

# Neurology<sup>®</sup>

## **Diagnosis and management of dementia with Lewy bodies: Third report of the DLB consortium**

I. G. McKeith, D. W. Dickson, J. Lowe, et al.

*Neurology* 2005;65:1863-1872 Published Online before print October 19, 2005

DOI 10.1212/01.wnl.0000187889.17253.b1

**This information is current as of October 19, 2005**

The online version of this article, along with updated information and services, is located on the World Wide Web at:

<http://www.neurology.org/content/65/12/1863.full.html>

*Neurology*® is the official journal of the American Academy of Neurology. Published continuously since 1951, it is now a weekly with 48 issues per year. Copyright . All rights reserved. Print ISSN: 0028-3878. Online ISSN: 1526-632X.





# Diagnosis and management of dementia with Lewy bodies

## Third report of the DLB consortium

I.G. McKeith, MD, FMedSci; D.W. Dickson, MD; J. Lowe, DM; M. Emre, MD; J.T. O'Brien, DM; H. Feldman, MDCM; J. Cummings, MD; J.E. Duda, MD; C. Lippa, MD; E.K. Perry, DSc; D. Aarsland, MD; H. Arai, MD; C.G. Ballard, MD; B. Boeve, MD; D.J. Burn, FRCP; D. Costa, MD; T. Del Ser, MD, PhD; B. Dubois, MD; D. Galasko, MD; S. Gauthier, MD, FRCPC; C.G. Goetz, MD; E. Gomez-Tortosa, MD, PhD; G. Halliday, PhD; L.A. Hansen, MD; J. Hardy, PhD; T. Iwatsubo, MD; R.N. Kalara, FRCPath; D. Kaufer, MD; R.A. Kenny, MD; A. Korczyn, MD; K. Kosaka, MD; V.M.-Y. Lee, PhD, MBA; A. Lees, MD; I. Litvan, MD; E. Londos, MD, PhD; O.L. Lopez, MD; S. Minoshima, MD, PhD; Y. Mizuno, MD; J.A. Molina, MD; E.B. Mukaetova-Ladinska, MD, PhD; F. Pasquier, MD, PhD; R.H. Perry, DSc; J.B. Schulz, MD; J.Q. Trojanowski, MD, PhD; and M. Yamada, MD, PhD, for the Consortium on DLB\*

**Abstract**—The dementia with Lewy bodies (DLB) Consortium has revised criteria for the clinical and pathologic diagnosis of DLB incorporating new information about the core clinical features and suggesting improved methods to assess them. REM sleep behavior disorder, severe neuroleptic sensitivity, and reduced striatal dopamine transporter activity on functional neuroimaging are given greater diagnostic weighting as features suggestive of a DLB diagnosis. The 1-year rule distinguishing between DLB and Parkinson disease with dementia may be difficult to apply in clinical settings and in such cases the term most appropriate to each individual patient should be used. Generic terms such as Lewy body (LB) disease are often helpful. The authors propose a new scheme for the pathologic assessment of LBs and Lewy neurites (LN) using alpha-synuclein immunohistochemistry and semiquantitative grading of lesion density, with the pattern of regional involvement being more important than total LB count. The new criteria take into account both Lewy-related and Alzheimer disease (AD)-type pathology to allocate a probability that these are associated with the clinical DLB syndrome. Finally, the authors suggest patient management guidelines including the need for accurate diagnosis, a target symptom approach, and use of appropriate outcome measures. There is limited evidence about specific interventions but available data suggest only a partial response of motor symptoms to levodopa: severe sensitivity to typical and atypical antipsychotics in ~50%, and improvements in attention, visual hallucinations, and sleep disorders with cholinesterase inhibitors.

NEUROLOGY 2005;65:1863–1872

**Clinical diagnostic criteria for DLB.** Since the publication of Consensus criteria for clinical and pathologic diagnosis of dementia with Lewy bodies (DLB),<sup>1,2</sup> new information indicates that clinical criteria for probable DLB have acceptable specificity, but suboptimal sensitivity.<sup>3,4</sup> Reasons identified in-

clude difficulties in recognition of the core feature fluctuation<sup>5,6</sup> and a low rate of all core features (fluctuation, visual hallucinations, parkinsonism) in the presence of neocortical, neurofibrillary tangle (NFT) pathology.<sup>7-9</sup> The criteria have therefore been modified (table 1) to incorporate additional items indicative of LB pathology. Distinction is made between clinical features or investigations that are *suggestive* of DLB, i.e., have been demonstrated to be significantly more frequent than in

Additional material related to this article can be found on the *Neurology* Web site. Go to [www.neurology.org](http://www.neurology.org) and scroll down the Table of Contents for the December 27 issue to find the title link for this article.

*This article was previously published in electronic format as an Expedited E-Pub on October 19, 2005, at [www.neurology.org](http://www.neurology.org).*

\*Author affiliations are listed in the appendix at the end of this article. Members of the Consortium on DLB are listed in appendix E-1 at [www.neurology.org](http://www.neurology.org). The third International Workshop meeting on DLB held in Newcastle upon Tyne in September 2003, was supported by unrestricted project grants in excess of \$10,000 from Amersham Health, Novartis Pharma, Pfizer/Eisai, and Shire Pharmaceuticals. Dr. I.G. McKeith has received sponsorship and research grants from Novartis, Pfizer/Eisai, Janssen Cilag, and GE Healthcare, Dr. J.T. O'Brien from GE Healthcare, Dr. H. Feldman from Janssen Pharma, Pfizer/Eisai, and Novartis, and Dr. C. Lippa from Amersham Health, Novartis, Pfizer/Eisai, and Shire.

A follow-up meeting of some of the participants in the workshop in September 2004 in Washington, DC, was supported by the NIH (NIA/National Institute of Neurological Disorders and Stroke).

Received February 24, 2005. Accepted in final form August 2, 2005.

Address correspondence and reprint requests to Professor I.G. McKeith, Institute for Ageing and Health, Wolfson Research Centre, Newcastle General Hospital, Westgate Road, Newcastle upon Tyne NE4 6BE, UK; e-mail: [i.g.mckeith@ncl.ac.uk](mailto:i.g.mckeith@ncl.ac.uk)

**Table 1** Revised criteria for the clinical diagnosis of dementia with Lewy bodies (DLB)

1. *Central feature* (essential for a diagnosis of possible or probable DLB)  
Dementia defined as progressive cognitive decline of sufficient magnitude to interfere with normal social or occupational function. Prominent or persistent memory impairment may not necessarily occur in the early stages but is usually evident with progression. Deficits on tests of attention, executive function, and visuospatial ability may be especially prominent.
2. *Core features* (two core features are sufficient for a diagnosis of probable DLB, one for possible DLB)  
Fluctuating cognition with pronounced variations in attention and alertness  
Recurrent visual hallucinations that are typically well formed and detailed  
Spontaneous features of parkinsonism
3. *Suggestive features* (If one or more of these is present in the presence of one or more core features, a diagnosis of probable DLB can be made. In the absence of any core features, one or more suggestive features is sufficient for possible DLB. Probable DLB should not be diagnosed on the basis of suggestive features alone.)  
REM sleep behavior disorder  
Severe neuroleptic sensitivity  
Low dopamine transporter uptake in basal ganglia demonstrated by SPECT or PET imaging
4. *Supportive features* (commonly present but not proven to have diagnostic specificity)  
Repeated falls and syncope  
Transient, unexplained loss of consciousness  
Severe autonomic dysfunction, e.g., orthostatic hypotension, urinary incontinence  
Hallucinations in other modalities  
Systematized delusions  
Depression  
Relative preservation of medial temporal lobe structures on CT/MRI scan  
Generalized low uptake on SPECT/PET perfusion scan with reduced occipital activity  
Abnormal (low uptake) MIBG myocardial scintigraphy  
Prominent slow wave activity on EEG with temporal lobe transient sharp waves
5. A diagnosis of DLB is *less likely*  
In the presence of cerebrovascular disease evident as focal neurologic signs or on brain imaging  
In the presence of any other physical illness or brain disorder sufficient to account in part or in total for the clinical picture  
If parkinsonism only appears for the first time at a stage of severe dementia
6. *Temporal sequence of symptoms*  
DLB should be diagnosed when dementia occurs before or concurrently with parkinsonism (if it is present). The term Parkinson disease dementia (PDD) should be used to describe dementia that occurs in the context of well-established Parkinson disease. In a practice setting the term that is most appropriate to the clinical situation should be used and generic terms such as LB disease are often helpful. In research studies in which distinction needs to be made between DLB and PDD, the existing 1-year rule between the onset of dementia and parkinsonism DLB continues to be recommended. Adoption of other time periods will simply confound data pooling or comparison between studies. In other research settings that may include clinicopathologic studies and clinical trials, both clinical phenotypes may be considered collectively under categories such as LB disease or alpha-synucleinopathy.

other dementing disorders, and *supportive* features, which commonly occur but with lower specificity. Clinicians should adopt a high index of suspicion, screening all patients with dementia for possible DLB (one core or one suggestive feature) paying particular attention to the early clinical presentation.<sup>7,10</sup> The widespread use of improved assessment tools and methods of investigation should further improve diagnostic accuracy.

*Progressive disabling mental impairment is a mandatory requirement for the diagnosis of DLB.* This statement<sup>1</sup> remains true although it is apparent that disability in DLB derives not only from cognitive impairment but also from neuropsychiatric, motoric, sleep, and autonomic dysfunction. The cognitive profile of DLB comprises both cortical and sub-

cortical impairments with substantial attentional deficits and prominent executive and visuospatial dysfunction.<sup>11,12</sup> A “double discrimination” can help differentiate DLB from Alzheimer disease (AD), with relative preservation of confrontation naming and short and medium term recall as well as recognition, and greater impairment on verbal fluency, visual perception and performance tasks.<sup>13-15</sup> Patients with DLB with neocortical neurofibrillary tangles (NFTs) often lack this profile, showing pronounced memory deficits more characteristic of AD. Composite global cognitive assessment tools such as the Mini-Mental State Examination (MMSE) cannot be relied upon to distinguish DLB from other common dementia syndromes and some patients who meet criteria for DLB will score in the normal range.

*DLB and dementia associated with Parkinson disease (PDD).* Many patients with PD develop dementia, typically 10 years or more after onset of motor symptoms.<sup>16,17</sup> Other than age at onset, temporal course, and possibly levodopa responsiveness,<sup>18,19</sup> no major differences between DLB and PDD have been found in any variable examined including cognitive profile,<sup>20</sup> attentional performance,<sup>21</sup> neuropsychiatric features,<sup>22</sup> sleep disorders,<sup>23</sup> autonomic dysfunction,<sup>24</sup> type and severity of parkinsonism,<sup>25</sup> neuroleptic sensitivity,<sup>26</sup> and responsiveness to cholinesterase inhibitors.<sup>27,28</sup> The relative contributions of LB formation and synuclein pathology, AD-type pathology, neuron loss, or neurochemical deficits as determinants of dementia in PD remain unresolved although recent studies suggest that Lewy-related pathology is more strongly associated than AD-type changes.<sup>29-31</sup>

The distinction between DLB and PDD as two distinct clinical phenotypes based solely on the temporal sequence of appearance of symptoms has been criticized by those who regard the different clinical presentations as simply representing different points on a common spectrum of LB disease, itself underpinned by abnormalities in alpha-synuclein metabolism. This unitary approach to classification may be preferable for molecular and genetic studies and for developing therapeutics. Descriptive labels that include consideration of the temporal course are preferred for clinical, operational definitions. DLB should be diagnosed when dementia occurs before or concurrently with parkinsonism and PDD should be used to describe dementia that occurs in the context of well-established PD. The appropriate term will depend upon the clinical situation and generic terms such as LB disease are often helpful. In research studies in which distinction is made between DLB and PDD, the 1-year rule between the onset of dementia and parkinsonism for DLB should be used. Adoption of other time periods will simply confound data pooling or comparison between studies. In other research settings including pathologic studies and clinical trials, both clinical phenotypes may be considered collectively under categories such as LB disease or alpha-synucleinopathy.

*Core features.* Although no major amendments to the three core features of DLB are proposed, improved methods for their clinical assessment are recommended for use in diagnosis and measurement of symptom severity.

*Fluctuation.* It is the evaluation of fluctuation that causes the greatest difficulty in clinical practice.<sup>32</sup> Inter-rater reliability is said to be low<sup>5,6</sup> although reports have generally been based upon review of pre-existing case records and notes, rather than direct rating of patients. Questions such as “are there episodes when his/her thinking seems quite clear and then becomes muddled?” were previously suggested as useful probes, but two recent studies<sup>33,34</sup> found 75% of both AD and DLB carers to respond positively. More detailed questioning and qualitative analysis of carers’ replies is therefore needed. The

Clinician Assessment of Fluctuation scale<sup>35</sup> requires an experienced clinician to judge the severity and frequency of “fluctuating confusion” or “impaired consciousness” over the previous month. The semi-structured One Day Fluctuation Assessment scale<sup>35</sup> can be administered by less experienced raters and generates a cut-off score to distinguish DLB from AD or vascular dementia (VaD). The Mayo Fluctuations Composite Scale<sup>34</sup> requires three or more “yes” responses from caregivers to structured questions about the presence of daytime drowsiness and lethargy, daytime sleep >2 hours, staring into space for long periods, or episodes of disorganized speech, as suggestive of DLB rather than AD. Recording variations in attentional performance using a computer based test system offers an independent method of measuring fluctuation, which is also sensitive to drug treatment effects.<sup>36</sup> Which of these various available methods is most appropriate will depend upon the setting and the level of expertise available. It is recommended that at least one formal measure of fluctuation is used when applying DLB diagnostic criteria and that staff are appropriately trained in its use.

*Visual hallucinations.* Recurrent, complex visual hallucinations (VH) continue to be one of the most useful signposts to a clinical diagnosis of DLB. They are generally present early in the course of illness with characteristics as described in the original report.<sup>1</sup> Informant-based assessment tools such as the Neuropsychiatric Inventory (NPI)<sup>37</sup> are helpful both for screening for VH and assessing their severity and frequency but do not always distinguish them from hallucinations in other sensory modalities. Caregivers tend to under-report VH and patients with mild to moderate cognitive impairment can contribute useful information about their presence and quality.<sup>38</sup> Patients with DLB with VH show more profound visuoperceptual dysfunction compared to those without hallucinations.<sup>39,40</sup> Increased numbers of LB in the anterior and inferior temporal lobe and amygdala at autopsy are associated with the presence and onset of VH,<sup>41</sup> each of these areas being implicated in the generation of complex visual images. Brain perfusion imaging demonstrates reduced occipital uptake<sup>42,43</sup> in areas identified as primary and secondary visual cortex.<sup>44</sup> VH are associated with greater deficits in cortical acetylcholine<sup>45,46</sup> and their presence may predict a good response to cholinergic therapy.<sup>47</sup>

*Parkinsonism.* The severity of extrapyramidal motor features in DLB is generally similar to that of age-matched patients with PD with or without dementia<sup>26</sup> with an average 10% annual progression rate.<sup>48</sup> There is an axial tendency with greater postural instability, gait difficulty, and facial immobility<sup>49</sup> than in non-demented patients with PD. Rest tremor is less common. The assessment of motor features may be complicated by the presence of cognitive impairment. A simple, five-item subscale of the Unified PD Rating Scale (UPDRS)<sup>50,51</sup> contains only those items that can reliably be assessed in DLB

independent of severity of dementia (tremor at rest, action tremor, body bradykinesia, facial expression, rigidity). Levodopa responsiveness in DLB<sup>18,19</sup> is almost certainly less than in uncomplicated PD, possibly because of intrinsic striatal degeneration<sup>52</sup> and the fact that a significant proportion of the parkinsonian symptoms may be non-dopaminergic in origin.

*Suggestive features.* If one or more of these is present, in addition to one or more core features, a diagnosis of probable DLB should be made. Possible DLB can be diagnosed if one or more suggestive features is present in a patient with dementia even in the absence of any core features. Suggestive features therefore have a similar diagnostic weighting as core clinical features but are not in the light of current knowledge considered sufficient, even in combination, to warrant a diagnosis of probable DLB in the absence of any core feature.

*REM sleep behavior disorder.* REM sleep behavior disorder (RBD) is manifested by vivid and often frightening dreams during REM sleep, but without muscle atonia. Patients therefore appear to “act out their dreams” vocalizing, flailing limbs, and moving around the bed sometimes violently. Vivid visual images are often reported, although the patient may have little recall of these episodes. The history is obtained from the bed partner, who may report many years of this sleep disorder prior to the onset of dementia and parkinsonism.<sup>53</sup> RBD is frequently associated with an underlying synucleinopathy—PD, DLB, or multiple system atrophy (MSA)—and only rarely with other neurodegenerative disorders.<sup>54</sup> Associated sleep disorders in DLB including excessive daytime drowsiness may also contribute to the fluctuating pattern. Screening questions about the presence of day and night time sleep disturbance should always be asked, facilitated by the use of sleep questionnaires, particularly those that query bed partners about a history of repeated episodes of “acting out dreams.”<sup>23</sup> The diagnosis of RBD may be confirmed by polysomnography.

*Severe neuroleptic sensitivity.* Deliberate pharmacologic challenge with D<sub>2</sub> receptor blocking agents should not be used as a diagnostic strategy for DLB because of the high morbidity and mortality associated with neuroleptic sensitivity reactions,<sup>55</sup> which are characterized by the acute onset or exacerbation of parkinsonism and impaired consciousness.<sup>56</sup> Approximately 50% of patients with DLB receiving typical or atypical antipsychotic agents do not react so adversely and a history of neuroleptic tolerance does not therefore exclude a diagnosis of DLB. A positive history of severe neuroleptic sensitivity is, by contrast, strongly suggestive of DLB.

*Dopamine transporter imaging.* Functional imaging of the dopamine transporter (DAT) defines integrity of the nigrostriatal dopaminergic system and currently has its main clinical application in assisting diagnosis of patients with tremor of uncertain etiology.<sup>57</sup> Imaging with specific ligands for DAT, e.g., FP-CIT, beta-CIT, IPT, TRODAT, provides a

marker for presynaptic neuronal degeneration. DAT imaging is abnormal in idiopathic PD, MSA, and progressive supranuclear palsy (PSP). Low striatal DAT activity also occurs in DLB but is normal in AD,<sup>58</sup> making DAT scanning particularly useful in distinguishing between the two disorders.<sup>59,60</sup>

*Supportive features.* These are features (see table 1) that are commonly present in DLB but lack sufficient diagnostic specificity to be categorized as core or suggestive. Routine enquiry should be made about such symptoms since patients and carers may not consider them related to the dementing process. Severe autonomic dysfunction may occur early in disease, producing orthostatic hypotension, neurocardiovascular instability, urinary incontinence, constipation, and impotence, as well as eating and swallowing difficulties.<sup>61-63</sup> Autonomic dysfunction may also contribute to repeated falls and syncope and the transient losses of consciousness that are seen in some patients with DLB.<sup>64</sup> Systematized delusions, hallucinations in other modalities, and depression may all occur during the course of DLB and if they are prominent early, they can lead to diagnostic confusion with late onset psychosis, delusional depression, or other primary psychiatric diagnoses.<sup>10,65</sup>

*Exclusion features.* Careful exclusion of other systemic or neurologic disorders that may explain the clinical presentation is essential. Particular difficulty exists in relation to attributing clinical significance to evidence of cerebrovascular disease, since pathologic and imaging studies suggest that white matter lesions (periventricular and deep white matter), microvascular changes, and lacunes may be present in up to 30% of autopsy confirmed DLB cases.<sup>66,67</sup> A diagnosis of DLB with cerebrovascular disease may sometimes be the most appropriate.

*Special investigations.* A recent review concluded that there are as yet no clinically applicable genotypic or CSF markers to support a diagnosis of DLB.<sup>3,68</sup> The role of DAT transporter scanning has already been discussed. Other imaging investigations can also be helpful, including preservation of hippocampal and medial temporal lobe volume on MRI,<sup>69,70</sup> atrophy of the putamen,<sup>71</sup> and occipital hypoperfusion (SPECT) and hypometabolism (PET)<sup>42,43,72-74</sup> without occipital atrophy on MRI.<sup>75</sup> Other features such as the degree of generalized atrophy, rate of progressive brain atrophy, and severity of white matter lesions do not aid in differential diagnosis from other dementia subtypes.<sup>76,77</sup> Scintigraphy with [I-123] metaiodobenzyl guanidine (MIBG),<sup>78</sup> which enables the quantification of postganglionic sympathetic cardiac innervation, is reduced in DLB and has been suggested to have high sensitivity and specificity in the differential diagnosis from AD.<sup>79</sup> Confirmatory studies with larger patient numbers are required. The standard EEG may show early slowing, epoch by epoch fluctuation, and transient temporal slow wave activity.<sup>3</sup>

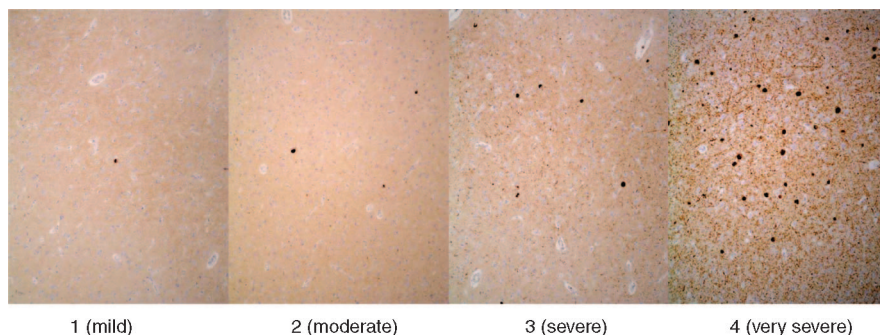


Figure. Staging of alpha-synuclein pathology in dementia with Lewy bodies (DLB). Alpha-synuclein immunostaining in cerebral cortex of DLB cases illustrating increasing severity of Lewy bodies (LBs) and LB pathology scored as stages 1 to 4. Stage 1 = sparse LBs or Lewy neurites (LNs); Stage 2 = >1 LB per high power field and sparse LNs; Stage 3 =  $\geq 4$  LBs and scattered LNs in low power field; Stage 4 = numerous LBs and LNs. Images courtesy

of Dr. E. Jaros. 5  $\mu$ m thick sections, pretreated with pressure cooker for 1 minute in EDTA pH8; Vector Elite Kit, Novocastra mouse monoclonal alpha-synuclein antibody (clone KM51), 1:30 dilution, DAB final reaction product.

### Pathologic assessment and diagnostic criteria for DLB.

*Dementia with Lewy bodies as a pathologic diagnostic category.* DLB was originally defined as a clinicopathologic entity with a specific constellation of clinical features, and a descriptive approach was proposed for assessing neuropathology.<sup>1</sup> The only neuropathologic requirement for DLB was the presence of LBs somewhere in the brain of a patient with a clinical history of dementia. Other pathologic features, e.g., senile plaques and neuron loss, could occur, but they were not inclusive or exclusive to the diagnosis. In many but not all cases the neuropathologic findings conform to those previously described as limbic or diffuse LB disease.<sup>80,81</sup> This liberal definition has the advantage of being widely inclusive, bringing many neuropathologic cases into consideration for DLB; however, as increasingly sensitive methods for detecting LBs have been developed, as many as 60% of AD cases may be considered to meet pathologic criteria for DLB using the 1996 criteria. Virtually none of these patients will have had the DLB clinical syndrome as described above, especially those cases with extensive NFTs<sup>8,9</sup> or those with one or more LBs in the amygdala but without significant Lewy-related pathology in other brain regions.<sup>82</sup> The inclusion of such cases as pathologically confirmed DLB has contributed to a view that the clinical criteria have suboptimal sensitivity.<sup>4</sup>

New recommendations are proposed that take into account both the extent of Lewy-related pathology and AD-type pathology in assessing the degree of certainty that the neuropathologic findings explain the DLB clinical syndrome. The scheme proposed should provide increased diagnostic specificity, since cases in which LBs are detected in the setting of extensive AD-type pathology that is likely to obscure the clinical features of the DLB syndrome are now classified as having a “low likelihood” of DLB.

*Identification of Lewy bodies and Lewy-related pathology.* LBs and Lewy neurites (LN) are pathologic aggregations of alpha-synuclein. They are also associated with intermediate filaments, chaperone proteins, and elements of the ubiquitin-proteasome system, indicating a role of the aggresomal response,

but these features are not specific for LBs and are found in other neuronal inclusions.<sup>83,84</sup>

While hematoxylin and eosin (H&E) histologic staining may be adequate for detection of brainstem type LBs, it is not sufficient for cortical LBs and it is incapable of detecting LNs. Ubiquitin immunohistochemistry, which unequivocally stains LBs and LNs, can only be recommended in cases with minimal concurrent AD-type pathology, since ubiquitin is also present in NFTs, which can be easily confused with LBs. Rather than ubiquitin immunohistochemistry, it is now more appropriate to use immunohistochemical staining for alpha-synuclein, since this has been shown to be the most sensitive and specific method currently available for detecting LBs and Lewy-related pathology. We also recommend a semiquantitative grading of lesion density rather than the counting methods previously proposed (see figure).

*Brain sampling and evaluation of Lewy-related pathology.* The scheme previously proposed<sup>1</sup> for characterization of regional involvement of the brain with respect to LB pathology, i.e., brainstem, limbic, and diffuse cortical types, as well as the recommended tissue sampling procedures, remains unchanged. The previous Consortium protocol advised counting LB density in five cortical regions with a summed score for the overall LB rating. Given the poor inter-rater reliability of counting of LBs, the new recommendations propose a semiquantitative grading of severity of Lewy-related pathology into mild, moderate, severe, and very severe, along lines similar to those used to grade SP and NFTs by the CERAD protocol.

*Brain sampling and evaluation of AD-type pathology in DLB.* At the time of the original statement there was considerable uncertainty about the significance of coexisting AD-type pathology<sup>85</sup> and the most widely used method for evaluating AD-type pathology was the CERAD protocol.<sup>86</sup> Subsequently, a working group of the NIA-Reagan Institute expanded upon the CERAD protocol, which used a plaque-based diagnostic algorithm, by adding assessments of topographic stages of neurofibrillary pathology.<sup>87</sup> As well as adding NFTs to the diagnostic algorithm, the NIA-Reagan criteria admit that the

**Table 2** Assignment of Lewy body type based upon pattern of Lewy-related pathology in brainstem, limbic, and neocortical regions

Lewy body type pathology	Brainstem regions			Basal forebrain/limbic regions				Neocortical regions		
	IX-X	LC	SN	nbM	Amygdala	Transentorhinal	Cingulate	Temporal	Frontal	Parietal
Brainstem-predominant	1-3	1-3	1-3	0-2	0-2	0-1	0-1	0	0	0
Limbic (transitional)	1-3	1-3	1-3	2-3	2-3	1-3	1-3	0-2	0-1	0
Diffuse neocortical	1-3	1-3	1-3	2-3	3-4	2-4	2-4	2-3	1-3	0-2

Brain regions are as defined anatomically in the original Consensus report.<sup>1</sup>

IX = 9th cranial nerve nucleus; X = 10th cranial nerve nucleus; LC = locus ceruleus; SN = substantia nigra; nbM = nucleus basalis of Meynert.

fit between clinical and pathologic features is imperfect and that the best that can be accomplished at present is a probability statement about the likelihood that the neuropathologic findings account for dementia. This approach has been adopted in the proposed DLB criteria which assess the likelihood that the neuropathologic findings predict the clinical syndrome of DLB. The likelihood that the observed neuropathology explains the DLB clinical syndrome is *directly related to the severity of Lewy-related pathology, and inversely related to the severity of concurrent AD-type pathology*. This approach is based on studies that demonstrate that clinical diagnostic accuracy for DLB is higher in patients with low burdens of AD-type pathology.<sup>7,8,88</sup> This revision is prompted by the body of literature that deals with clinicopathologic correlations in DLB and the desire to implement more rigorous and specific neuropathologic criteria than currently exist. The proposal obviously requires further research to test its validity. The proposal can be summarized as follows.

- Cases should be assigned a likelihood that the dementia can be attributed to AD pathology using the NIA-Reagan criteria, which employs the CERAD method for assessing neuritic plaques<sup>86</sup> and a topographic staging method for neurofibrillary degeneration comparable to that proposed by Braak and Braak.<sup>89</sup>
- Lewy body type pathology should be assigned according to the previous guidelines in the original Consensus report.<sup>1</sup> Semiquantitative grading of Lewy body severity should be adopted rather than counting LB in various brain regions.
- The following scoring system for LB is recommended (figure):

0 = None

1 = Mild (sparse LBs or LNs)

2 = Moderate (more than one LB in a low power field and sparse LNs)

3 = Severe (four or more LBs and scattered LNs in a low power field)

4 = Very severe (numerous LBs and numerous LNs)

While brainstem nuclei are affected in virtually every case of LB disease, the severity of brainstem pathology is highly variable. Similarly, there is a range of severity of involvement in the various limbic and neocortical regions; thus, for most areas a range of severity is acceptable. The pattern of regional involvement is more important than total LB count. Table 2 presents a scheme for assigning LB disease type by assessing the regional pattern of Lewy-related pathology using CERAD-like scoring for LB.

Table 3 shows criteria for allocating a probability that neuropathologic findings will be associated with a DLB clinical syndrome taking account of both AD and LB type pathology.

As in the NIA-Reagan criteria, SP types should be subclassified as diffuse and neuritic but for diagnostic purposes, only neuritic plaques should be considered.

Specification for the assessment of vascular pathology in DLB was made in the original consensus statement document and in the absence of further significant research findings it is recommended to continue using this approach.

*Neuropathologic research strategies.* A scheme to stage Lewy-related pathology in the brain has been proposed for PD.<sup>90</sup> The validity of staging and its relevance to DLB remains to be determined by its application to brains of prospectively studied individuals with a range of cognitive and extrapyramidal dysfunction. Similarly, while considerable research has been reported on Lewy-related pathology in the amygdala and periamygdaloid cortex using immunostaining for alpha-synuclein, additional studies are warranted in prospectively studied cohorts in order to understand possible clinical correlates of this pathology in DLB as well as in AD, where this may be the only brain region with alpha-synuclein pathology.<sup>91,92</sup> Critical to this issue is the clinical significance, if any, of this pattern of alpha-synuclein pathology. As such, the presence or absence of LB in the amygdala should be documented in all cases of dementia reaching neuropathologic autopsy. Determining the presence of alpha-synuclein pathology in the amygdala in other dementias is a related research objective.

It is clear from several case studies that familial cases of DLB occur<sup>93,94</sup> and that LBs are commonly

**Table 3** Assessment of the likelihood that the pathologic findings are associated with a DLB clinical syndrome

	Alzheimer type pathology		
	NIA-Reagan Low (Braak stage 0–II)	NIA-Reagan Intermediate (Braak stage III–IV)	NIA-Reagan High (Braak stage V–VI)
Lewy body type pathology			
Brainstem-predominant	Low	Low	Low
Limbic (transitional)	High	Intermediate	Low
Diffuse neocortical	High	High	Intermediate

DLB = dementia with Lewy bodies; NIA = National Institute on Aging.

seen in familial cases of AD.<sup>95</sup> There are recent reports that triplication of the alpha-synuclein gene (SNCA) can cause DLB, PD, and PDD whereas gene duplication is associated only with motor PD, suggesting a gene dose effect.<sup>96</sup> However, SCNA multiplication is not found in most patients with LB disease.<sup>97</sup> Continued clinical, pathologic, and genetic evaluation of familial cases of DLB and AD is therefore an important and potential highly informative area for continued research.

**Clinical management.** Patient management in DLB is complex and includes early detection, investigation, diagnosis, and treatment of cognitive impairment; assessment and management of neuropsychiatric and behavioral symptoms; treatment of the movement disorder; and monitoring and management of autonomic dysfunction and sleep disorders.<sup>98</sup> The evidence base for making recommendations about the management of DLB is limited and what follows is based upon consensus opinion of clinicians experienced in treating DLB.

**Nonpharmacologic interventions.** Nonpharmacologic interventions have the potential to ameliorate many of the symptoms and functional impairments associated with DLB, but none has yet been systematically evaluated. Cognitive dysfunction and associated symptoms such as VH can for example be exacerbated by low levels of arousal and attention and strategies to increase these by social interaction and environmental novelty may reduce their presence and impact.

**Pharmacologic treatments.** Motor parkinsonism. Levodopa can be used for the motor disorder of both DLB and PDD.<sup>18,19</sup> Medication should generally be introduced at low doses and increased slowly to the minimum required to minimize disability without exacerbating psychiatric symptoms. Anticholinergics should be avoided.

Neuropsychiatric symptoms. Visual hallucinations are the most commonly experienced psychiatric symptom and are often accompanied by delusions, anxiety, and behavioral disturbance. When pharmacologic intervention is required the options include cholinesterase inhibitors (CHEIs) or atypical antipsychotic medications. Open label studies have demonstrated the effectiveness of all three generally

available CHEIs in DLB and PDD but placebo controlled trial data are only available to date for rivastigmine.<sup>27,28</sup> The reported reduction in symptom frequency and intensity of VH appears to be mediated at least in part by improved attentional function and the presence of VH is associated with greater cognitive improvement.<sup>47</sup> Side effects of hypersalivation, lacrimation, and urinary frequency may occur, in addition to the usual gastrointestinal symptoms, and a dose dependent exacerbation of extrapyramidal motor features may occur in a minority. If CHEIs are ineffective or if more acute symptom control of behavior is required, it may be difficult to avoid a cautious trial of an atypical antipsychotic. The clinician should warn both the carer and patient of the possibility of a severe sensitivity reaction.<sup>26</sup> Typical antipsychotics should be avoided.<sup>55</sup> Novel atypicals with potentially more favorable pharmacologic properties, such as quetiapine, clozapine, and aripiprazole, may have theoretical advantages over traditional agents in LB disease<sup>99–101</sup> but controlled clinical trial data are needed.

Depression is common in both DLB and PDD and there have been no systematic studies of its management. At the present time SSRI and SNRIs are probably preferred pharmacologic treatment. Tricyclic antidepressants and those with anticholinergic properties should generally be avoided. Apathy is also common and may improve with CHEIs.<sup>27</sup> Sleep disorders are frequently seen in LB disease and may be an early feature. RBD can be treated with clonazepam 0.25 mg at bedtime, melatonin 3 mg at bedtime, or quetiapine 12.5 mg at bedtime and titrated slowly monitoring for both efficacy and side effects.<sup>53</sup> CHEIs may be helpful for disturbed sleep.<sup>102</sup>

Cognitive symptoms. CHEIs may be of benefit for the fluctuating cognitive impairments with impact on global function and activities of daily living.<sup>103</sup> The effect size in DLB is reported as being generally larger than seen with the same drugs when used in AD.<sup>104</sup> Only limited data on long-term effects are available<sup>105</sup> and there are none about possible disease-modifying effects.

#### Acknowledgment

The authors thank Maureen Middlemist and Lynn Patterson for administrative support.



## Author affiliations

From the Institute for Ageing and Health (Drs. McKeith, O'Brien, E.K. Perry, Burn, Kalaria, Kenny, Mukaetova-Ladinska, and R.H. Perry), University of Newcastle upon Tyne, UK; Department of Neuropathology (Dr. Dickson), Mayo Clinic Jacksonville, FL; Division of Pathology (Dr. Lowe), School of Molecular Medical Sciences, University of Nottingham, UK; Department of Neurology (Dr. Emre), Istanbul University, Istanbul Faculty of Medicine, Turkey; UBC Division of Neurology (Dr. Feldman), University of British Columbia, Vancouver, Canada; Department of Neurology (Dr. Cummings), UCLA Medical School Alzheimer's Disease Center, Los Angeles, CA; Parkinson's Disease Research, Education and Clinical Center (Dr. Duda), Philadelphia VAMC, PA; Memory Disorders Program (Dr. Lippa), Drexel University School of Medicine, Philadelphia, PA; Section of Geriatric Psychiatry (Dr. Aarsland), Stavanger University Hospital, Norway; Department of Geriatric & Respiratory Medicine (Dr. Arai), Tohoku University School of Medicine, Miyagi, Japan; Wolfson Centre for Age-Related Diseases (Dr. Ballard), London, UK; Department of Neurology (Dr. Boeve), Mayo Clinic, Rochester, MN; Institute of Nuclear Medicine (Dr. Costa), HPP Medicina Molecular, SA, Porto, Portugal; Section of Neurology (Dr. del Ser), Hospital Severo Ochoa, Madrid, Spain; Hopital La Salpêtrière (Dr. Dubois), Paris, France; Depts. of Neuroscience (Dr. Galasko) and Pathology (Dr. Hansen), University of California San Diego, La Jolla; MCSA Alzheimer's Disease Research Unit (Dr. Gauthier), McGill Centre for Studies in Aging, Quebec, Canada; Department of Neurological Sciences (Dr. Goetz), Rush University Medical Center, Chicago, IL; Fundación Jiménez Díaz (Dr. Gómez-Tortosa), Servicio de Neurología, Madrid, Spain; Prince of Wales Medical Research Institute (Dr. Halliday), Sydney, Australia; Laboratory of Neurogenetics (Dr. Hardy), National Institute on Aging, Bethesda, MD; Department of Neuropathology & Neuroscience (Dr. Iwatsubo), University of Tokyo, Japan; Dept. of Neurology CB 7025 (Dr. Kaufer), University of North Carolina School of Medicine, Chapel Hill; Department of Neurology (Dr. Korczyn), Tel-Aviv University, Israel; Department of Psychiatry (Dr. Kosaka), Fukushima Hospital, Toyohashi, Japan; Center for Neurodegenerative Disease Research (Drs. Lee and Trojanowski), University of Pennsylvania School of Medicine, Philadelphia; Reta Lila Weston Institute of Neurological Studies (Dr. Lees), Royal Free & UCL Medical School, London, UK; Department of Neurology (Dr. Litvan), Movement Disorder Program, University of Louisville School of Medicine, KY; Department of Clinical Sciences (Dr. Londo), University Hospital, Malmö, Sweden; Neuropsychology Research Program (Dr. Lopez), University of Pittsburgh Medical College, PA; Department of Radiology (Dr. Minoshima), University of Washington, Seattle; Department of Neurology (Dr. Mizuno), Juntendo University School of Medicine, Tokyo, Japan; Servicio de Neurología (Dr. Molina), Hospital 12 de Octubre, Madrid, Spain; Clinique Neurologique (Dr. Pasquier), Centre Hospitalier et Universitaire, Lille, France; Department of Neurodegeneration and Restorative Research Center of Neurological Medicine (Dr. Schulz), University of Göttingen, Germany; and Department of Neurology & Neurobiology of Ageing (Dr. Yamada), Kanazawa University Graduate School of Medical Science, Kanazawa, Japan.

## References

1. McKeith IG, Galasko D, Kosaka K, et al. Consensus guidelines for the clinical and pathologic diagnosis of dementia with Lewy bodies (DLB): report of the consortium on DLB international workshop. *Neurology* 1996;47:1113–1124.
2. McKeith IG, Perry EK, Perry RH. Report of the second dementia with Lewy body international workshop. *Neurology* 1999;53:902–905.
3. McKeith I, Mintzer J, Aarsland D, et al. Dementia with Lewy bodies. *Lancet Neurol* 2004;3:19–28.
4. Litvan I, Bhatia KP, Burn DJ, et al. SIC Task Force Appraisal of clinical diagnostic criteria for parkinsonian disorders. *Mov Disord* 2003;18:467–486.
5. Luis CA, Barker WW, Gajraj K, et al. Sensitivity and specificity of three clinical criteria for dementia with Lewy bodies in an autopsy-verified sample. *Int J Geriatr Psychiatry* 1999;14:526–533.
6. Mega MS, Masterman DL, Benson F, et al. Dementia with Lewy bodies: reliability and validity of clinical and pathologic criteria. *Neurology* 1996;47:1403–1409.
7. Del Ser T, Hachinski V, Merskey H, Munoz DG. Clinical and pathologic features of two groups of patients with dementia with Lewy bodies: effect of coexisting Alzheimer-type lesion load. *Alzheimer Dis Assoc Disord* 2001;15:31–44.
8. Merdes AR, Hansen LA, Jeste DV, et al. Influence of Alzheimer pathology on clinical diagnostic accuracy in dementia with Lewy bodies. *Neurology* 2003;60:1586–1590.
9. Ballard CG, Jacoby R, Del Ser T, et al. Neuropathological substrates of psychiatric symptoms in prospectively studied patients with autopsy-confirmed dementia with Lewy bodies. *Am J Psychiatry* 2004;161:843–849.
10. McKeith IG, Perry RH, Fairbairn AF, Jabeen S, Perry EK. Operational criteria for senile dementia of Lewy body type (SDLT). *Psychol Med* 1992;22:911–922.
11. Collerton D, Burn D, McKeith I, O'Brien J. Systematic review and meta-analysis show that dementia with Lewy bodies is a visual-

perceptual and attentional-executive dementia. *Dement Geriatr Cogn Disord* 2003;16:229–237.

12. Calderon J, Perry RJ, Erzincliglu SW, Berrios GE, Denning TR, Hodges JR. Perception, attention, and working memory are disproportionately impaired in dementia with Lewy bodies compared with Alzheimer's disease. *J Neurol Neurosurg Psychiatry* 2001;70:157–164.
13. Walker Z, Allan RL, Shergill S, Katona CLE. Neuropsychological performance in Lewy body dementia and Alzheimer's disease. *Br J Psychiatry* 1997;170:156–158.
14. Connor DJ, Salmon DP, Sandy TJ, Galasko D, Hansen LA, Thal LJ. Cognitive profiles of autopsy-confirmed Lewy body variant vs pure Alzheimer disease. *Arch Neurol* 1998;55:994–1000.
15. Mormont E, Grymonprez LL, Baisset-Mouly C, Pasquier F. The profile of memory disturbance in early Lewy body dementia differs from that in Alzheimer's disease. *Rev Neurol* 2003; 159: 762–766.
16. Aarsland D, Andersen K, Larsen JP, Lolk A, Kragh-Sorensen P. Prevalence and characteristics of dementia in Parkinson disease: an 8-year prospective study. *Arch Neurol* 2003;60:387–392.
17. Emre M. Dementia associated with Parkinson's disease. *Lancet Neurol* 2003;2:229–237.
18. Molloy S, McKeith I, O'Brien JT, Burn D. The role of levodopa in the management of dementia with Lewy bodies. *J Neurol Neurosurg Psychiatry* 2005 76:1200–1203.
19. Bonelli SB, Ransmayr G, Steffelbauer M, Lukas T, Lampl C, Deibl M. L-dopa responsiveness in dementia with Lewy bodies, Parkinson disease with and without dementia. *Neurology* 2004;63:376–378.
20. Aarsland D, Litvan I, Salmon D, Galasko D, Wentzel-Larsen T, Larsen JP. Performance on the dementia rating scale in Parkinson's disease with dementia and dementia with Lewy bodies: comparison with progressive supranuclear palsy and Alzheimer's disease. *J Neurol Neurosurg Psychiatry* 2003;74:1215–1220.
21. Ballard CG, Aarsland D, McKeith IG, et al. Fluctuations in attention: PD dementia vs DLB with parkinsonism. *Neurology* 2002;59:1714–1720.
22. Aarsland D, Ballard C, Larsen JP, McKeith I. A comparative study of psychiatric symptoms in dementia with Lewy bodies and Parkinson's disease with and without dementia. *Int J Geriatr Psychiatry* 2001;16: 528–536.
23. Boeve BF, Silber MH, Ferman TJ, et al. REM sleep behaviour disorder and degenerative dementia. An association likely reflecting Lewy body disease. *Neurology* 1998;51:363–370.
24. Wenning GK, Scherfler C, Granata R, et al. Time course of symptomatic orthostatic hypotension and urinary incontinence in patients with postmortem confirmed parkinsonian syndromes: a clinicopathological study. *J Neurol Neurosurg Psychiatry* 1999;67:620–623.
25. Aarsland D, Ballard C, McKeith I, Perry RH, Larsen JP. Comparison of extrapyramidal signs in dementia with Lewy bodies and Parkinson's disease. *J Neuropsychiatry Clin Neurosci* 2001;13:374–379.
26. Aarsland D, Ballard C, Larsen JP, McKeith I, O'Brien J, Perry R. Marked neuroleptic sensitivity in dementia with Lewy bodies and Parkinson's disease. *J Clin Psychiatry* 2005;66:633–637.
27. McKeith I, Del-Ser T, Spano PF, et al. Efficacy of rivastigmine in dementia with Lewy bodies: a randomised, double-blind, placebo-controlled international study. *Lancet* 2000;356:2031–2036.
28. Emre M, Aarsland D, Albanese A, et al. Rivastigmine for dementia associated with Parkinson's disease. *N Engl J Med* 2004;351:2509–2518.
29. Apaydin H, Ahlskog E, Parisi JE, Boeve BF, Dickson DW. Parkinson disease neuropathology. Later-developing dementia and loss of levodopa response. *Arch Neurol* 2002;59:102–112.
30. Hurtig HI, Trojanowski JQ, Galvin J, et al. Alpha-synuclein cortical Lewy bodies correlate with dementia in Parkinson's disease. *Neurology* 2000;54:1916–1921.
31. Kovari E, Gold G, Giannakopoulos P, Lovero P, Surini M, Bouras C. Lewy body pathology in different neurodegenerative diseases. *Brain Pathol* 2000;10:518–519.
32. Cummings JL. Fluctuations in cognitive function in dementia with Lewy bodies. *Lancet Neurol* 2004;3:266.
33. Bradshaw JSM, Hopwood M, Anderson V, Brodtmann A. Fluctuating cognition in dementia with Lewy bodies and Alzheimer's disease is qualitatively distinct. *J Neurol Neurosurg Psychiatry* 2004;75:382–387.
34. Ferman TJ, Smith GE, Boeve BF, et al. DLB fluctuations: specific features that reliably differentiate from AD and normal aging. *Neurology* 2004;62:181–187.
35. Walker MP, Ayre GA, Cummings JL, et al. The Clinician Assessment of Fluctuation and the One Day Fluctuation Assessment Scale. Two methods to assess fluctuating confusion in dementia. *Br J Psychiatry* 2000;177:252–256.
36. Walker MP, Ayre GA, Cummings JL, et al. Quantifying fluctuation in dementia with Lewy bodies, Alzheimer's disease and vascular dementia. *Neurology* 2000;54:1616–1624.
37. Cummings JL, Mega M, Gray K, Rosenberg-Thompson S, Carusi DA, Gornbein J. The Neuropsychiatric Inventory: comprehensive assessment of psychopathology in dementia. *Neurology* 1994;44:2308–2314.

38. Mosimann UP, Rowan EN, Partington CE, et al. Characteristics of visual hallucinations in Parkinson's disease dementia and dementia with Lewy bodies. *Am J Geriatr Psychiatry* (in press).
39. Mori E, Shimomura T, Fujimori M, et al. Visuo-perceptual impairment in dementia with Lewy bodies. *Arch Neurol* 2000;57:489-493.
40. Mosimann UP, Mather G, Wesnes K, O'Brien J, Burn D, McKeith IG. Visual perception in Parkinson disease dementia and dementia with Lewy bodies. *Neurology* 2004;63:2091-2096.
41. Harding AJ, Broe GA, Halliday GM. Visual hallucinations in Lewy body disease relate to Lewy bodies in the temporal lobe. *Brain* 2002;125:391-403.
42. Lobotesis K, Fenwick JD, Phipps A, et al. Occipital hypoperfusion on SPECT in dementia with Lewy bodies but not AD. *Neurology* 2001;56:643-649.
43. Colloby SJ, Fenwick JD, Williams ED, et al. A comparison of 99mTc-HMPAO SPECT changes in dementia with Lewy bodies and Alzheimer's disease using statistical parametric mapping. *Eur J Nucl Med* 2002;29:615-622.
44. Higuchi M, Tashiro M, Arai H, et al. Glucose hypometabolism and neuropathological correlates in brains of dementia with Lewy bodies. *Exp Neurol* 2000;162:247-256.
45. Perry EK, McKeith I, Thompson P, et al. Topography, extent, and clinical relevance of neurochemical deficits in dementia of Lewy body type, Parkinson's disease and Alzheimer's disease. *Ann NY Acad Sci* 1991;640:197-202.
46. Ballard C, Piggott M, Johnson M, et al. Delusions associated with elevated muscarinic binding in dementia with Lewy bodies. *Ann Neurol* 2000;48:868-876.
47. McKeith IG, Wesnes KA, Perry E, Ferrara R. Hallucinations predict attentional improvements with rivastigmine in dementia with Lewy bodies. *Dement Geriatr Cogn Disord* 2004;18:94-100.
48. Ballard C, O'Brien J, Swann A, et al. One year follow-up of parkinsonism in dementia with Lewy bodies. *Dement Geriatr Cogn Disord* 2000;11:219-222.
49. Burn DJ, Rowan EN, Minnett T, et al. Extrapyrarnidal features in Parkinson's disease with and without dementia and dementia with Lewy bodies: a cross-sectional comparative study. *Mov Disord* 2003;18:884-889.
50. Fahn S, Elton RL. Unified Parkinson's Disease Rating Scale. In: Fahn S, Marsden CD, Goldstein M, Calne DB, eds. *Recent developments in Parkinson's disease*. New York: McMillan, 1987;153-163.
51. Ballard C, McKeith I, Burn D, et al. The UPDRS scale as a means of identifying extrapyramidal signs in patients suffering from dementia with Lewy bodies. *Acta Neurol Scand* 1997;96:366-371.
52. Duda JE, Giasson BI, Mabon ME, Lee VMY, Trojanowski JQ. Novel antibodies to synuclein show abundant striatal pathology in Lewy body diseases. *Ann Neurol* 2002;52:205-210.
53. Boeve BF, Silber MH, Ferman TJ. REM sleep behavior disorder in Parkinson's disease and dementia with Lewy bodies. *J Geriatr Psychiatry Neurol* 2004;17:146-157.
54. Boeve BF, Silber MH, Parisi JE, et al. Synucleinopathy pathology and REM sleep behavior disorder plus dementia or parkinsonism. *Neurology* 2003;61:40-45.
55. McKeith I, Fairbairn A, Perry R, Thompson P, Perry E. Neuroleptic sensitivity in patients with senile dementia of Lewy body type. *BMJ* 1992;305:673-678.
56. Swanberg MM, Cummings JL. Benefit-risk considerations in the treatment of dementia with Lewy bodies. *Drug Safety* 2002;25:511-523.
57. Marshall V, Grosset D. Role of dopamine transporter imaging in routine clinical practice. *Mov Disord* 2003;18:1415-1423.
58. Piggott MA, Marshall EF, Thomas N, et al. Striatal dopaminergic markers in dementia with Lewy bodies, Alzheimer's and Parkinson's diseases: rostrocaudal distribution. *Brain* 1999;122:1449-1468.
59. O'Brien JT, Colloby SJ, Fenwick J, et al. Dopamine transporter loss visualised with FP-CIT SPECT in dementia with Lewy bodies. *Arch Neurol* 2004;61:919-925.
60. Walker Z, Costa DC, Walker RWH, et al. Differentiation of dementia with Lewy bodies from Alzheimer's disease using a dopaminergic pre-synaptic ligand. *J Neurol Neurosurg Psychiatry* 2002;73:134-140.
61. Horimoto Y, Matsumoto M, Akatsu H, et al. Autonomic dysfunctions in dementia with Lewy bodies. *J Neurol* 2003;250:530-533.
62. Kuzuhara S, Yoshimura M. Clinical and neuropathological aspects of diffuse Lewy body disease in the elderly. *Adv Neurol* 1993;60:464-469.
63. Del-Ser T, Munoz DG, Hachinski V. Temporal pattern of cognitive decline and incontinence is different in Alzheimer's disease and diffuse Lewy body disease. *Neurology* 1996;46:682-686.
64. Ballard C, Shaw F, McKeith I, Kenny RA. High prevalence of neurovascular instability in neurodegenerative dementias. *Neurology* 1998;51:1760-1762.
65. Birkett DP, Desouky A, Han L, Kaufman M. Lewy bodies in psychiatric patients. *Int J Geriatr Psychiatry* 1992;7:235-240.
66. Jellinger KA. Neuropathological spectrum of synucleinopathies. *Mov Disord* 2003;18(suppl 6): S2-12.
67. McKeith IG, Ballard CG, Perry RH, et al. Prospective validation of Consensus criteria for the diagnosis of dementia with Lewy bodies. *Neurology* 2000;54:1050-1058.
68. Galasko D. Biomarkers in non-Alzheimer dementias. *Clin Neurosci Res* 2004;3:375-381.
69. Barber R, Ballard C, McKeith IG, Gholkar A, O'Brien JT. MRI volumetric study of dementia with Lewy bodies. A comparison with AD and vascular dementia. *Neurology* 2000;54:1304-1309.
70. Barber R, Gholkar A, Scheltens P, Ballard C, McKeith IG, O'Brien JT. Medial temporal lobe atrophy on MRI in dementia with Lewy bodies. *Neurology* 1999;52:1153-1158.
71. Cousins DA, Burton EJ, Burn D, Gholkar A, McKeith IG, O'Brien JT. Atrophy of the putamen in dementia with Lewy bodies but not Alzheimer's disease: an MRI study. *Neurology* 2003;61:1191-1195.
72. Ishii K, Hosaka K, Mori T, Mori E. Comparison of FDG-PET and IMP-SPECT in patients with dementia with Lewy bodies. *Ann Nucl Med* 2004;18:447-451.
73. Albin RL, Minoshima S, Damato CJ, Frey KA, Kuhl DA, Sima AAF. Fluoro-deoxyglucose positron emission tomography in diffuse Lewy body disease. *Neurology* 1996;47:462-466.
74. Minoshima S, Foster NL, Sima AAF, Frey KA, Albin RL, Kuhl DE. Alzheimer's disease versus dementia with Lewy bodies: cerebral metabolic distinction with autopsy confirmation. *Ann Neurol* 2001;50:358-365.
75. Middelkoop HAM, van der Flier WM, Burton EJ, et al. Dementia with Lewy bodies and AD are not associated with occipital lobe atrophy on MRI. *Neurology* 2001;57:2117-2120.
76. Barber R, Gholkar A, Scheltens P, Ballard C, McKeith IG, O'Brien JT. MRI volumetric correlates of white matter lesions in dementia with Lewy bodies and Alzheimer's disease. *Int J Geriatr Psychiatry* 2000;15:911-916.
77. O'Brien JT, Paling S, Barber R, et al. Progressive brain atrophy on serial MRI in dementia with Lewy bodies, AD, and vascular dementia. *Neurology* 2001;56:1386-1388.
78. Yoshita M, Taki J, Yamada M. A clinical role for I-123 MIBG myocardial scintigraphy in the distinction between dementia of the Alzheimer's-type and dementia with Lewy bodies. *J Neurol Neurosurg Psychiatry* 2001;71:583-588.
79. Taki J, Yoshita M, Yamada M, Tonami N. Significance of I-123-MIBG scintigraphy as a pathophysiological indicator in the assessment of Parkinson's disease and related disorders: It can be a specific marker for Lewy body disease. *Ann Nucl Med* 2004;18:453-461.
80. Kosaka K. Lewy bodies in cerebral cortex. Report of three cases. *Acta Neuropathol* 1978;42:127-134.
81. Kosaka K, Yoshimura M, Ikeda K, Budka H. Diffuse type of Lewy body disease: progressive dementia with abundant cortical Lewy bodies and senile changes of varying degree—A new disease? *Clin Neuropathol* 1984;3:185-192.
82. Hamilton RL. Lewy bodies in Alzheimer's disease: a neuropathological review of 145 cases using alpha-synuclein immunohistochemistry. *Brain Pathol* 2000;10:378-384.
83. McNaught KS, Shashidharan P, Perl DP, Jenner P, Olanow CW. Aggresome-related biogenesis of Lewy bodies. *Eur J Neurosci* 2002;16:2136-2148.
84. Tanaka M, Kim YM, Lee G, Junn E, Iwatsubo T, Mouradian MM. Aggregates formed by alpha-synuclein and synphilin-1 are cytoprotective. *J Biol Chem* 2004;279:4625-4631.
85. Lippa CF, McKeith I. Dementia with Lewy bodies: improving diagnostic criteria. *Neurology* 2003;60:1571-1572.
86. Mirra SS, Heyman A, McKeel D, et al. The Consortium to Establish a Registry for Alzheimer's Disease (CERAD) II. Standardisation of the neuropathological assessment of Alzheimer's disease. *Neurology* 1991;41:479-486.
87. NIA. Consensus recommendations for the postmortem diagnosis of Alzheimer's disease. The National Institute on Aging, and Reagan Institute Working Group on Diagnostic Criteria for the Neuropathological Assessment of Alzheimer's Disease. *Neurobiol Aging* 1997;18(4 suppl):s1-2.
88. Lopez OL, Becher JT, Kaufer DI, et al. Research evaluation and prospective diagnosis of dementia with Lewy bodies. *Arch Neurol* 2002;59:43-46.
89. Harding AJ, Kril JJ, Halliday GM. Practical measures to simplify the Braak tangle staging method for routine pathological screening. *Acta Neuropathol* 2000;99:199-208.
90. Braak H, Del Tredici K, Rub U, de Vos RAI, Steur E, Braak E. Staging of brain pathology related to sporadic Parkinson's disease. *Neurobiol Aging* 2003;24:197-211.
91. Lippa CF, Fujiwara H, Mann DM, et al. Lewy bodies contain altered alpha-synuclein in brains of many familial Alzheimer's disease patients with mutations in presenilin and amyloid precursor protein genes. *Am J Pathol* 1998;153:1365-1370.
92. Popescu A, Lippa CF, Lee VMY, Trojanowski JQ. Lewy bodies in the amygdala: increase of alpha-synuclein aggregates in neurodegenerative diseases with tau-based inclusions. *Arch Neurol* 2004;61:1915-1919.

93. Tsuang DW, DiGiacomo L, Bird TD. Familial occurrence of dementia with Lewy bodies. *Am J Geriatr Psychiatry* 2004;12:179–188.
94. Gwinn-Hardy K, Singleton AA. Familial Lewy body diseases. *J Geriatr Psychiatry Neurol* 2002;15:217–223.
95. Trembath Y, Rosenberg C, Ervin JF, et al. Lewy body pathology is a frequent co-pathology in familial Alzheimer's disease. *Acta Neuropathol* 2003;105:484–488.
96. Singleton A, Gwinn-Hardy K. Parkinson's disease and dementia with Lewy bodies: a difference in dose? *Lancet* 2004;364:1105–1107.
97. Johnson J, Hague SM, Hanson M, et al. SNCA multiplication is not a common cause of Parkinson disease or dementia with Lewy bodies. *Neurology* 2004;63:554–556.
98. Barber R, Panikkar A, McKeith IG. Dementia with Lewy bodies: diagnosis and management. *Int J Geriatr Psychiatry* 2001;16:S12–S18.
99. Fernandez HH, Wu CK, Ott BR. Pharmacotherapy of dementia with Lewy bodies. *Exp Opin Pharmacother* 2003;4:2027–2037.
100. Terao T, Shimomura T, Izumi Y, Nakamura J. Two cases of quetiapine augmentation for donepezil-refractory visual hallucinations in dementia with Lewy bodies. *J Clin Psychiatry* 2003;64:1520–1521.
101. Burke WJ, Pfeiffer RF, McComb RD. Neuroleptic sensitivity to clozapine in dementia with Lewy bodies. *J Neuropsychiatry Clin Neurosci* 1998;10:227–229.
102. Reading PJ, Luce AK, McKeith IG. Rivastigmine in the treatment of parkinsonian psychosis and cognitive impairment. *Mov Disord* 2001;16:1171–1174.
103. Aarsland D, Mosimann UP, McKeith IG. Role of cholinesterase inhibitors in Parkinson's disease and dementia with Lewy bodies. *J Geriatr Psychiatry Neurol* 2004;17:164–171.
104. Samuel W, Caligiuri M, Galasko D, et al. Better cognitive and psychopathologic response to donepezil in patients prospectively diagnosed as dementia with Lewy bodies: a preliminary study. *Int J Geriatr Psychiatry* 2000;15:794–802.
105. Grace J, Daniel S, Stevens T, et al. Long-term use of rivastigmine in patients with dementia with Lewy bodies: An open-label trial. *Int Psychogeriatr* 2001; 13: 199–205.

**Diagnosis and management of dementia with Lewy bodies: Third report of the DLB consortium**

I. G. McKeith, D. W. Dickson, J. Lowe, et al.

*Neurology* 2005;65:1863-1872 Published Online before print October 19, 2005

DOI 10.1212/01.wnl.0000187889.17253.b1

**This information is current as of October 19, 2005**

<b>Updated Information &amp; Services</b>	including high resolution figures, can be found at: <a href="http://www.neurology.org/content/65/12/1863.full.html">http://www.neurology.org/content/65/12/1863.full.html</a>
<b>Supplementary Material</b>	Supplementary material can be found at: <a href="http://www.neurology.org/content/suppl/2007/04/02/01.wnl.0000187889.17253.b1.DC2.html">http://www.neurology.org/content/suppl/2007/04/02/01.wnl.0000187889.17253.b1.DC2.html</a> <a href="http://www.neurology.org/content/suppl/2005/12/20/01.wnl.0000187889.17253.b1.DC1.html">http://www.neurology.org/content/suppl/2005/12/20/01.wnl.0000187889.17253.b1.DC1.html</a>
<b>References</b>	This article cites 98 articles, 41 of which you can access for free at: <a href="http://www.neurology.org/content/65/12/1863.full.html##ref-list-1">http://www.neurology.org/content/65/12/1863.full.html##ref-list-1</a>
<b>Citations</b>	This article has been cited by 100 HighWire-hosted articles: <a href="http://www.neurology.org/content/65/12/1863.full.html##otherarticles">http://www.neurology.org/content/65/12/1863.full.html##otherarticles</a>
<b>Subspecialty Collections</b>	This article, along with others on similar topics, appears in the following collection(s): <b>All Cognitive Disorders/Dementia</b> <a href="http://www.neurology.org/cgi/collection/all_cognitive_disorders_dementia">http://www.neurology.org/cgi/collection/all_cognitive_disorders_dementia</a> <b>Alzheimer's disease</b> <a href="http://www.neurology.org/cgi/collection/alzheimers_disease">http://www.neurology.org/cgi/collection/alzheimers_disease</a> <b>Dementia with Lewy bodies</b> <a href="http://www.neurology.org/cgi/collection/dementia_with_lewy_bodies">http://www.neurology.org/cgi/collection/dementia_with_lewy_bodies</a>
<b>Permissions &amp; Licensing</b>	Information about reproducing this article in parts (figures, tables) or in its entirety can be found online at: <a href="http://www.neurology.org/misc/about.xhtml#permissions">http://www.neurology.org/misc/about.xhtml#permissions</a>
<b>Reprints</b>	Information about ordering reprints can be found online: <a href="http://www.neurology.org/misc/addir.xhtml#reprintsus">http://www.neurology.org/misc/addir.xhtml#reprintsus</a>

