

# Richard A. Hopper, M.D., M.S.

- Cleft Lip and Palate
- Syndromic Severe Midface Hypoplasia
- Craniosynostosis



FUNDING  
CHRMC Craniofacial Endowment Fund  
KLS Martin Ltd.

**C**raniofacial surgery is a relatively new subspecialty of Plastic Surgery, being officially initiated at the 4th Congress of the International Confederation for Plastic and Reconstructive Surgery in Rome in 1967. Since then it has become an active field of clinical and basic science research with the goal of improving the treatment of a broad spectrum of reconstructive procedures of the cranium and face. Our research is focused on the treatment of three specific birth defects affecting children: cleft lip and palate, syndromic midface hypoplasia, and craniosynostosis.

identified before they demonstrate failure to grow, their diets could be tailored to prepare them for surgery.

We have initiated a study to measure the metabolic rates of infants with cleft lip and/or cleft palate using indirect calorimetry, and to compare these with clinical measurements such as weight gain, growth, and diagnosis. The study is taking place at the Craniofacial Center at Children's Hospital and Regional Medical Center. It will enroll 30 children a year in the study and follow them during the first year of their life, before and after each of their surgeries. The goal of the study is to create

---

*Since midface distraction osteogenesis is a relatively new technique in evolution, we are actively researching ways to improve the process at the Craniofacial Center of Children's Hospital.*

---

## Clinical Research

### Cleft Lip and Palate

Children born with a cleft lip and/or palate require intensive multi-disciplinary care from the day they are diagnosed to the time they stop growing. In the first year of life the children undergo two fundamental operations; repair of their cleft lip and nose deformity at age three months, and repair of their palate at age one year. The goal of research in this field is to optimize these two operations so that the need for multiple secondary surgeries during early childhood and adolescence is minimized.

One way to optimize surgeries is to ensure that the infants are well nourished in preparation for the stress and post-operative healing of the procedure. From clinical experience we have identified a sub-group of infants with cleft lip and palate who do not gain weight and grow appropriately, despite standard of care feeding and nutritional intervention. If these infants can be

new guidelines for the nutritional care of infants with cleft lip and palate based on their individual needs.

### Syndromic Severe Midface Hypoplasia

Children born with syndromes such as those described by Apert, Crouzon, and Pfeiffer can have such poor growth of their upper facial skeleton, or midface, that it compromises the closure of their eyelids and therefore the protection of their vision, the airway of their nose and therefore their ability to sleep, and the relationship between their upper and lower jaws and their ability to chew. The recognized surgical treatment of these children is to separate the upper facial skeleton from the rest of the skull, known as a LeFort III osteotomy, then to move the upper face forward and secure it in place with bone graft harvested from the child's ribs.

The limitations of this traditional Lefort III advancement are that some of the child's ribs need to be removed and, because of the tightness of the skin and

muscle overlying the upper facial skeleton, the face can usually only be moved forward around one centimeter. Repeat Lefort III operations, or inadequate advancements were therefore not uncommon in children with severe midface hypoplasia, or restricted growth.

Over the past ten years, a technique known as distraction osteogenesis has been used to treat severe midface hypoplasia (Figure 1). This involves performing a Lefort III osteotomy, but instead of advancement and bone grafting, the incisions are closed and a skull based distraction device is attached to the upper facial bones with wires. Over the next two to three weeks, the midface is slowly moved forward at a rate of 1 mm a day. This slow advancement allows the skin and muscle to adjust, such that advancements of up to three centimeters are possible. Once the advancement is complete, the device remains in place for two months while the fibrous tissue that has formed in the bone gap turns into solid bone. Bone grafts are therefore not needed.

Since midface distraction osteogenesis is a relatively new technique in evolution, we are actively researching ways to improve the process at the Craniofacial Center of Children's Hospital. A prospective Institutional Research Board (IRB) approved study is underway to examine the psychosocial impact of the three month long procedure on the patients and their families, and to suggest interventions to minimize the stress. Pre- and post-operative extensive sleep studies are being performed on all the children undergoing the procedure to examine the effect on quality of sleep.

Sequential radiographic imaging is being used to learn how the facial bones adjust, remodel, and grow after they have been advanced such a large distance. Timing of how long it takes the new bone to form behind the advanced facial bones is also being studied to determine the optimum time to remove the distraction device.

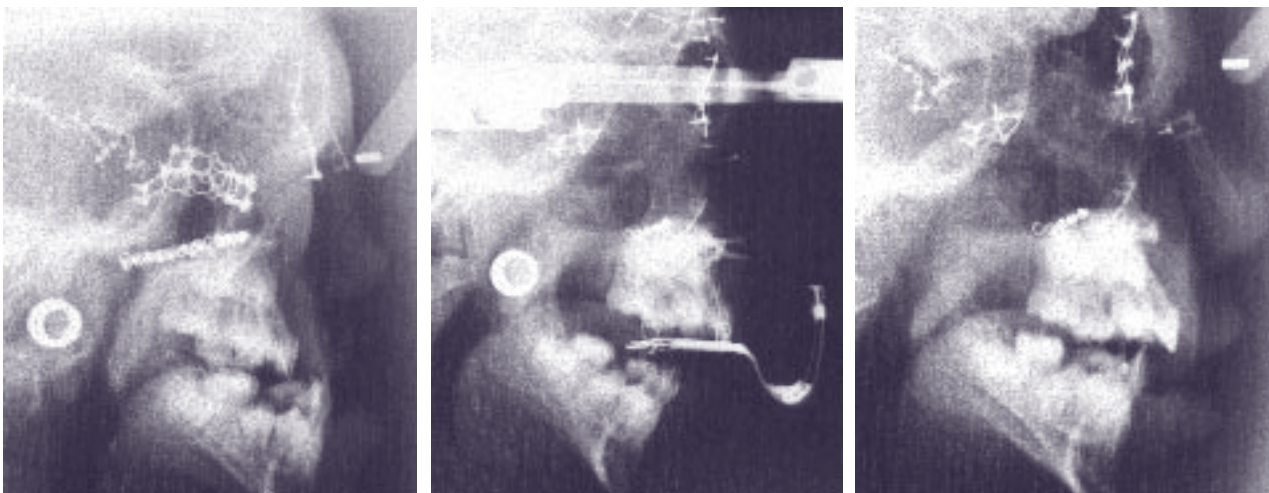
## Basic Science Research

### Craniosynostosis

Craniosynostosis is early fusion of one or more of the growth sutures of an infant's skull, resulting in a progressive deformity of the child's skull shape. In some cases craniosynostosis can also result in deviation of the position of the eyes and face, or can restrict the expansion of the brain as it grows. The majority of affected infants have isolated craniosynostosis with no family history of the birth defect and no other medical problems.

Unfortunately, the current treatment of craniosynostosis is to subject these otherwise healthy infants to a joint neurosurgery and craniofacial plastic surgery operation with the need for blood transfusions and the risks of severe morbidity, or in rare cases, mortality. The ideal treatment of isolated craniosynostosis would be to prevent the suture fusion from occurring by blocking the responsible abnormal molecular pathway.

There is a reliable sex ratio to the presentation of isolated craniosynostosis that has not been explained. Early closure of the sagittal or metopic sutures, both midline sutures, occurs predominantly in males. In contrast, coronal suture fusion is more common in



**FIGURE 1:** Lateral Cephalograms of a child undergoing midface distraction osteogenesis with an external device (Left) Before the operation, the child is having problems sleeping due to constriction of her nasopharynx, problems with dry eyes due to lack of cheek protection, and a problem chewing due to her upper jaw being well behind her lower jaw. (Middle) The facial bones have been separated from the skull and the external distraction device has slowly advanced them over a period of two weeks. This process is not painful, but involves frequent follow-up visits and parent support. (Right) After removal of the device, the advanced bone has healed in a favorable position, with a small over correction to allow for future mandible growth.

females. Our theory is that there is a subgroup of individuals with craniosynostosis whose bone cells, or osteoblasts, are more susceptible to the *in utero* effects of sex hormones. Both testosterone and estrogen are present in the uterine environment, and from research on osteoporosis in the elderly, both are known to increase osteoblast differentiation into mineralized bone.

With IRB approval, we have been collecting bone samples from children undergoing craniofacial surgery for craniosynostosis and creating osteoblast cultures from them. Now that we have established primary cell lines representing different types of craniosynostosis and different sexes, we are examining the effect of different concentrations of sex hormones on osteoblast growth, differentiation and selective gene upregulation. Our goal is to identify patients whose osteoblasts have an increased susceptibility to the effects of sex hormones and to determine the molecular reason for this susceptibility.

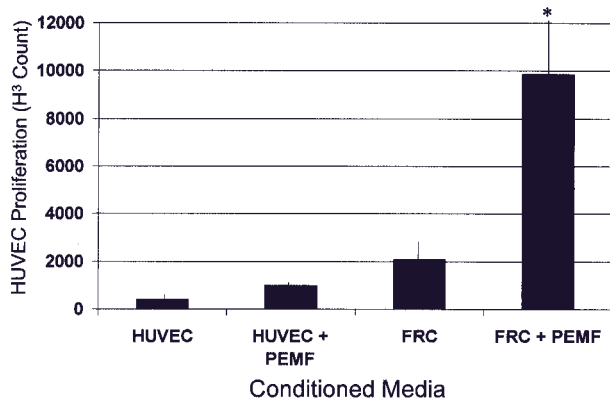
Osteoblasts cultured from fused sutures grow faster than osteoblasts cultured from open, or patent, sutures. The prevailing theory is that osteoblasts around fused sutures are abnormal, however our alternate theory is that there are cells within normal sutures that serve to inhibit the growth of surrounding osteoblasts to prevent premature suture closure. In craniosynostosis, this normal inhibitory mechanism is lost, and fusion occurs. To test this theory, we have cultured sub-populations of

cells grown from fused and open sutures in the same individual. We are examining differences in gene expression among these sub-populations and how one population can affect the growth of the other.

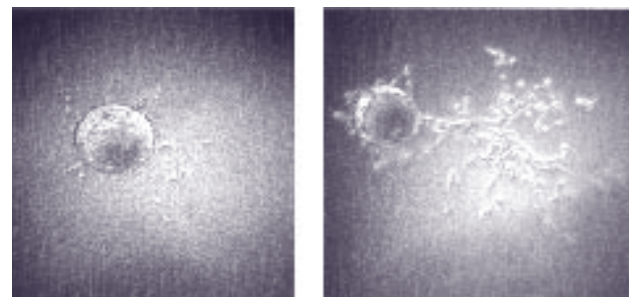
Osteoblasts do not exist in isolation in the skull. Bone healing involves a complex coordination between osteoblasts and adjacent blood vessel, or endothelial, cells. A collaborative project with Dr. Geoff Gurtner at New York University Medical Center has just been completed which examined the interaction of rat cranial osteoblasts with endothelial cells in the presence of pulsed electromagnetic fields (PEMF). We have found that when the osteoblasts were stimulated with PEMF, they secreted a protein that increased the growth rate of endothelial cells almost five fold (Figure 2).

This dramatic increase in blood vessel growth does not appear to be due to the well known vascular endothelial growth factor (VEGF), therefore the next phase of the project is to identify the protein responsible. PEMF was also shown to increase directly the formation of early blood vessels, or tubules, by the endothelial cells (Figure 3). These two observations help us to understand better the beneficial effects of PEMF on bone healing, and may eventually lead to ways to create the same effect without the use of cumbersome electromagnetic devices.

As an exciting extension of our continuing work on craniosynostosis osteoblasts, and osteoblast-endothelial cell interactions, we are collaborating with Professor Patrick Stayton of Bioengineering to use the technique of micropatterning to examine and manipulate cell-cell interactions in a controlled fashion.



**FIGURE 2:** The effect of media from osteoblasts and endothelial cells stimulated with a pulsed electromagnetic field (PEMF) on endothelial cell proliferation. When human endothelial cells (HUVEC) were grown in media from fetal rat osteoblasts stimulated with PEMF (FRC+PEMF), their rate of proliferation increased significantly (\*  $p < 0.05$ ) compared to media from unstimulated osteoblasts (FRC) and stimulated or unstimulated HUVEC.



**FIGURE 3:** The effect of pulsed electromagnetic fields (PEMF) on endothelial cell tubulization. Endothelial cells attached to microspheres formed significantly more tubules when exposed to PEMF (left) than when not exposed to the PEMF (right).

#### OTHER CO-INVESTIGATORS

Cassie Aspinall, MSW; CHRMC Craniofacial Center / Michael Cunningham, M.D., Ph.D.; UW Department of Pediatrics / Patrick Stayton, Ph.D.; UW Department of Bioengineering