

PEDIATRICS®

OFFICIAL JOURNAL OF THE AMERICAN ACADEMY OF PEDIATRICS

Healing of Hymenal Injuries in Prepubertal and Adolescent Girls: A Descriptive Study

John McCann, Sheridan Miyamoto, Cathy Boyle and Kristen Rogers
Pediatrics 2007;119:e1094-e1106; originally published online Apr 9, 2007;
DOI: 10.1542/peds.2006-0964

The online version of this article, along with updated information and services, is
located on the World Wide Web at:

<http://www.pediatrics.org/cgi/content/full/119/5/e1094>

PEDIATRICS is the official journal of the American Academy of Pediatrics. A monthly publication, it has been published continuously since 1948. PEDIATRICS is owned, published, and trademarked by the American Academy of Pediatrics, 141 Northwest Point Boulevard, Elk Grove Village, Illinois, 60007. Copyright © 2007 by the American Academy of Pediatrics. All rights reserved. Print ISSN: 0031-4005. Online ISSN: 1098-4275.

American Academy of Pediatrics

DEDICATED TO THE HEALTH OF ALL CHILDREN™



Healing of Hymenal Injuries in Prepubertal and Adolescent Girls: A Descriptive Study

John McCann, MD, Sheridan Miyamoto, MSN, FNP, Cathy Boyle, MSN, PNP, Kristen Rogers, PhD

Child and Adolescent Research and Evaluation (CAARE) Diagnostic and Treatment Center, University of California, Davis, Children's Hospital, Sacramento, California

The authors have indicated they have no financial relationships relevant to this article to disclose.

ABSTRACT

OBJECTIVE. The objective of this study was to identify the healing process and outcome of hymenal injuries in prepubertal and adolescent girls.

METHODS. This multicenter, retrospective project used photographs to document the healing process and outcome of hymenal trauma that was sustained by 239 prepubertal and pubertal girls whose ages ranged from 4 months to 18 years.

RESULTS. The injuries that were sustained by the 113 prepubertal girls consisted of 21 accidental or noninflicted injuries, 73 secondary to abuse, and 19 "unknown cause" injuries. All 126 pubertal adolescents were sexual assault victims. The hymenal injuries healed at various rates and except for the deeper lacerations left no evidence of the previous trauma. Abrasions and "mild" submucosal hemorrhages disappeared within 3 to 4 days, whereas "marked" hemorrhages persisted for 11 to 15 days. Only petechiae and blood blisters proved to be "markers" for determining the approximate age of an injury. Petechiae resolved within 48 hours in the prepubertal girls and 72 hours in the adolescents. A blood blister was detected at 34 days in an adolescent. As lacerations healed, their observed depth became shallower and their configuration smoothed out. Of the girls who sustained "superficial," "intermediate," or "deep" lacerations, 15 of 18 prepubertal girls had smooth and continuous appearing hymenal rims, whereas 24 of 41 adolescents' hymens had a normal, "scalloped" appearance and 30 of 34 had no disruption of continuity on healing. The final "width" of a hymenal rim was dependent on the initial depth of the laceration. No scar tissue formation was observed in either group of girls.

CONCLUSIONS. The hymenal injuries healed rapidly and except for the more extensive lacerations left no evidence of a previous injury. There were no significant differences in the healing process and the outcome of the hymenal injuries in the 2 groups of girls.

www.pediatrics.org/cgi/doi/10.1542/peds.2006-0964

doi:10.1542/peds.2006-0964

Key Words

accidental genital injuries, adolescent sexual assault, child abuse, child sexual abuse, forensic evidence, sexual assault, genital injuries, sexual abuse

Accepted for publication Nov 7, 2006

Address correspondence to John McCann, MD, 10788 NE Bill Point Dr, Bainbridge Island, WA 98011. E-mail: drjohnmccann@aol.com

Address requests for reprints to Cathy Boyle, MSN, PNP, CAARE Diagnostic and Treatment Center, Department of Pediatrics, UC Davis Children's Hospital, 3300 Stockton Blvd, Sacramento, CA 95820-1451. E-mail: cathy.boyle@ucdavis.edu

PEDIATRICS (ISSN Numbers: Print, 0031-4005; Online, 1098-4275). Copyright © 2007 by the American Academy of Pediatrics

THE EVALUATION OF the female child or adolescent who is suspected of having been sexually abused traditionally focuses on the condition of the hymenal membrane. Examinations that are performed shortly after an assault may disclose findings that are consistent with a recent injury. However, if an assault had taken place sometime in the past, then signs of trauma may have faded as the injuries healed. It is the interpretation of the nonacute examination findings that continues to be debated.

Until recently, there has been relatively little information in the medical literature regarding the healing process and the outcome of a female genital injury, particularly in the case of the prepubertal child.¹⁻³ The similarity between naturally occurring variations and a hymenal configuration that results from an injury further complicates the interpretation of a finding.⁴⁻¹²

As a hymenal laceration heals, it may or may not leave evidence of the previous injury. McCann et al² observed that hymenal lacerations healed rapidly and "smoothed off" over time. Kerns et al¹³ used the term "concave" to describe the multiple variations of healed hymenal lacerations. A recent article by Heppenstall-Heger et al³ reported that "partial" hymenal tears in 8 preadolescent girls healed "completely," whereas 5 had a "shallow notch" at the site of their injury. The findings that "persisted" were those that were created by a transection. Berenson et al¹⁴ reported that the only child with a hymenal rim 1 mm or less in width had a history of penile penetration. Unfortunately, there were too few cases to determine the statistical significance of that finding. Adams,¹⁵ in a commentary on normal hymenal findings, stated, "If there is a clear rim of hymenal tissue in the posterior aspect of the orifice, and the free edge of the hymen can be followed visually at least from the 9 o'clock to the 3 o'clock positions, when the patient is supine, this is likely to be a normal finding." This project was designed to explore further the findings in these and other reports while determining whether there is a "pattern," a "time sequence," or a "marker" in the healing process that could be used to determine the age of a hymenal injury.

METHODS

Recruitment

The patients of this multicenter study were recruited from medical centers throughout the United States. The majority of the cases were obtained through the use of the Helfer Honorary Society's List Server. The members of this society are recognized for their expertise in the evaluation and treatment of abused and neglected children and adolescents. The participants were asked to provide pertinent medical information and photographs of any female child or adolescent who had sustained a recent genital injury from any cause. Patients from birth

through 17 years of age were eligible. In addition to the photograph documentation of an injury, all patients were required to have at least 1 follow-up examination. Because this was a retrospective, convenience-sample study, the period between an injury and the follow-up examination was not uniform. Each center's institutional review board authorized its center's participation in the project.

Historical Information

The participants provided the authors with a summary of the portion of a patient's medical chart that pertained to the genital injury. The information requested included the individual's birth date and ethnicity, the examiner's opinion as to the cause of injury, and the examination method used. The time and date of all examinations became part of a computer-generated database. The patient's computerized medical chart and photographs were assigned a number to protect the individual's identity.

Photographic Documentation

Photographic documentation by the participating institutions was achieved through the use of a variety of recording methods. The most common recording device was a 35-mm camera with either a macrolens or a camera that was mounted on a colposcope. Several centers provided images that had been captured through the use of digital or video cameras. Prints of the images were provided by each center.

Analysis of the Photographs

The patients were examined by a variety of methods. These included the supine, labial separation method; the supine, labial traction technique; and the prone, knee-to-chest position approach. When a patient had been examined by >1 method, we divided the photographs into separate envelopes on the basis of the method used. Each photograph was evaluated in the presence of all 3 of the medical examiner authors. During the evaluation, the authors were blinded to the history that had been provided by the medical examiners from the contributing centers. An agreement by all 3 medical authors was required before the interpretation of a finding was recorded on a worksheet illustration and entered into the databank.

Analysis of the Patients

We divided the patients into 2 groups on the basis of the hormonal effect on the hymen. The first group consisted of the girls whose hymen showed no estrogen effect. Their hymens tended to be thin, delicate membranes with relatively smooth edges. The few girls who were younger than 3 years and retained some visual evidence of endogenous estrogen were placed in the first group, which is referred to as prepubertal girls. The second

group consisted of the older girls whose hymen did show an estrogen effect. Their hymens tended to be thicker and more redundant and frequently had scalloped edges. This second group is referred to as pubertal adolescents.

Types of Hymenal Injuries

We subdivided the hymenal injuries into abrasions, contusions, and lacerations. Evidence of a contusion included the presence of blood blisters, edema, hematomas, petechiae, and submucosal hemorrhages. The abrasions and contusions were classified further as to their size and color. We subdivided the hymenal membrane into quadrants for purposes of identifying the location of any abrasions or contusions. Regardless of the examination position used, the location of a hymeneal laceration was recorded as though the patient were in a supine position.

The lacerations were categorized according to both depth and configuration. The classification system that was used for the depth of the hymenal lacerations is similar to the one used by Berenson et al¹⁴ in their report on hymenal injury findings. We determined the depth of a hymenal laceration by comparing the width of the lacerated portion of the hymen with the width of an adjacent, uninjured portion of the membrane.

The depths of the hymenal lacerations were divided into (1) those that penetrated to <50% of the width of the membrane (superficial), (2) those that were approximately halfway through the membrane (intermediate), (3) those that went beyond the midpoint of the membrane (deep), (4) those that extended to the base (attachment) of the hymenal membrane (transection), and (5) those that went through the hymenal membrane attachment into the surrounding tissues (transection with an extension) (see Appendix).

The configuration system that was used to categorize a hymenal laceration's shape came from the authors' previous observation that the configuration of a hymenal laceration seemed to change as a laceration healed.² It had been noted that acute hymenal lacerations had a sharper V-shaped configuration, whereas the healed lacerations had a smoother, U-shaped appearance. We used this observation as the basis for exploring the possibility that these changes could be used to determine the approximate age of a healing hymenal laceration.

The configuration of a hymenal laceration included cleft-like patterns, whereby the wound edges remained relatively close together; V-shaped lacerations that had a sharp or pointed base; U-shaped configurations whose base was narrow but rounded; concavities whose base was both broad and rounded; and lacerations with a broad base and a narrow rim. The "healed" laceration category incorporated findings that could no longer be classified as a laceration. This included the presence of

new blood vessel formation (neovascularity) and scar tissue formation at the former location of a laceration.

Interobserver Reliability

Individually, we performed a blinded reexamination of a random sample of 10% ($n = 25$) of the cases to assess and measure the reliability of the original agreement on the interpretation of a finding. κ statistics were used to determine this interobserver reliability. The κ scores ranged from 0.46 to 1.0 (moderate to excellent). On the basis of the interpretation of κ results by Landis and Koch¹⁷ as well as Fleiss,¹⁸ the authors concluded that the results from this study are sufficiently reliable.

Statistical Analysis

We entered all collected data into an Access database. We documented the photographic findings on a worksheet and systematically entered it into the created database. These data were then transferred directly into SPSS (SPSS, Chicago, IL) for analysis. Descriptive statistics were used to show the results of each of the 3 examination methods. Data were analyzed using t tests, χ^2 , Yates continuity correction or Fisher's exact tests, and Mann-Whitney U tests, when appropriate. Statistical significance was defined as $P < .05$.

RESULTS

The patients consisted of 239 female children and adolescents from 4 months to 18 years of age. There were 113 (47%) prepubertal girls and 126 (53%) adolescent girls. Of the 113 prepubertal children, 50% were white, 16% were black, 26% were Hispanic, 4% were Asian, and 4% were of a mixed race. Of the 126 pubertal girls, 48% were white, 29% were black, 14% were Hispanic, 4% were Asian, and 6% were of a mixed race.

Timing of Examinations and the Cause of Injuries

The period between an injury and the initial examination ranged from 1 hour to 3 days. A total of 164 (69%) of the 239 patients were seen within 24 hours after their injury. A total of 208 (87%) were examined within 48 hours. The other 31 (13%) girls were first evaluated between 48 and 72 hours after their injury. The mean time between an injury and the first examination was 24 hours. The causes of the injuries as determined by the contributors of the 113 prepubertal girls included 21 (19%) accidental or noninflicted injuries, 73 (65%) injuries secondary to abuse, and 19 (17%) "unknown cause" injuries. All 126 pubertal adolescents were said to be victims of a sexual assault.

Summary of the Findings

Because of the nature of this study, the timing of both the initial and the follow-up examinations varied as a result of the circumstances of each case. During each follow-up examination, the number of days since the

injury and the status of each hymenal abrasion, contusion, or laceration were recorded. The 113 prepubertal girls had 201 hymenal abrasions and contusions. The soonest "reevaluation" of a girl occurred within 24 hours of her initial examination. The longest a prepubertal girl was followed was 2.5 years. The average follow-up period was 9.9 months. The 126 adolescents were found to have 230 hymenal abrasions and contusions. The period for a reevaluation after an assault ranged from 1 day to 3.7 months. The average follow-up period was 61 days.

Table 1 is a compilation of the period required for a hymenal abrasion or contusion to resolve. The healing process was recorded as follows:

- "Last detected" identifies the day in which a finding was last detected in patients with a particular injury.
- "Earliest disappearance" identifies the day in which a particular finding was no longer identified in any one patient.
- "Gone" identifies the first examination day in which a finding was no longer seen in any of the patients.
- "Never seen" represents a finding that was never seen in any of the patients during a follow-up examination. Unfortunately, in this case there was no way of knowing when such an injury had actually disappeared.

For example, of the 8 (7%) prepubertal girls with a hymenal abrasion (for which there were a total of 13 follow-up examinations), the only time this finding was seen on a follow-up examination in any of the patients was on the day following the initial evaluation (day 1) (see "Last Detected" column). No abrasions were detected in any of the other follow-up examinations, beginning with 2 girls who were reexamined on day 3 (see

"Earliest Disappearance" column). Day 3 was also the day after which no other hymenal abrasions were detected (see "Gone" column).

Hematoma is used as an example of the term "never seen" in Table 1. Five prepubertal girls had what initially appeared to be a hymenal "hematoma." The soonest any of these girls were reexamined was 2 days after their injury (day 2). At that time, as well as on all of the other follow-up examinations, the well-defined, localized collection of blood (hematoma) on their hymens had been replaced by diffuse submucosal hemorrhages. Therefore, a hematoma was "never seen" after the initial examination.

Hymenal Abrasions

See the previous example for the hymenal abrasions that were detected in the prepubertal girls. Only 2 (1%) adolescents had hymenal abrasions (Table 1). Their first reevaluation occurred on day 4, and, in both cases, the abrasions had disappeared, leaving only a localized area of erythema.

Hymenal Contusions

Blood Blisters

The thin vesicles of blood (blood blisters) on the surface of the hymen were associated with the more severely injured patients. Once formed, this small, blood-filled vesicle seemed to shrink in size before disappearing completely.

Only 1 prepubertal girl was discovered to have a hymenal blood blister (Table 1). Although the blood blister was present on the seventh day after the injury,

TABLE 1 Healing of Hymenal Abrasions and Contusions: Prepubertal and Pubertal Girls

Type of Injury	Group	Severity	Last Detected ^a	Earliest Disappearance ^b	Gone ^c	Never Seen ^d
Abrasions	Pre: 8 (7%), F/U: 13		1 d (1/1)	3 d (2/2)	3–22 d (10/10)	
	Pub: 2 (1%), F/U: 4		4 d (2/2)	11 d (2/2)	11 d (2/2)	
Blood blister	Pre: 1 (1%), F/U: 3		7 d (1/1)	30 d (1/1)	Unknown (1/1)	
	Pub: 7 (5%), F/U: 11		34 d (1/5)	9 d (1/5)	Unknown (1/1)	
Hematoma	Pre: 5 (4%), F/U: 5			1 d (2/2)		X (5/5)
	Pub: 13 (10%), F/U: 19		1 d (1/1)	3 d (5/5)	3–20 d (13/13)	
Petechiae	Pre: 69 (60%), F/U: 97		2 d (1/4)	1 d (2/3)	2–211 d (90/90)	
	Pub: 65 (50%), F/U: 80		3 d (1/7)	2 d (1/1)	3–109 d (72/72)	
Submucosal hemorrhages	Pre: 51 (45%), 118 submucosal hemorrhages	Mild: 8, F/U: 13	2 d (3/3)	3 d (1/1)	3–942 d (10/10)	
		Mod: 53, F/U: 70	8 d (1/34)	5 d (2/8)	10–304 d (28/28)	
		Mark: 57, F/U: 94	15 d (1/54)	5 d (3/18)	16–730 d (22/22)	
	Pub: 67 (53%), 137 submucosal hemorrhages	Mild: 16, F/U: 22	7 d (1/8)	4 d (4/4)	8–29 d (10/10)	
		Mod: 71, F/U: 80	12 d (2/48)	3 d (1/5)	14–36 d (37/37)	
		Mark: 50, F/U: 66	11 d (1/23)	3 d (1/5)	12–97 d (38/38)	

Values in parentheses represent the number of patients with a particular finding on any given day. Pre indicates prepubertal girls (nonestrogenized hymen); Pub, pubertal adolescents (estrogenized hymen); F/U, follow-up examinations; Mod, moderated; Mark, marked.

^a The day in which a finding was last seen during follow-up in all patients with this finding.

^b The first follow-up day in which a finding was not found in at least 1 patient with this finding.

^c The first follow-up day in which a finding is never again detected in any of the patients with this finding.

^d A finding is never seen in any follow-up of all of the patients with this finding.

TABLE 2 Location of Hymenal Lacerations: Comparison of Prepubertal and Pubertal Girls

Location	Prepubertal		Pubertal	
	<i>n</i>	%	<i>n</i>	%
Anterior	2	5	12	15
Lateral	3	8	18	23 ^a
Posterior ^a	35	88	50	61
Total	40	100	80	100

^a Significant at $P < .01$.

the actual time of resolution is unknown because she did not return for any additional reevaluations.

Seven (5%) adolescents had blood blisters on their hymenal membranes (Table 1). These lesions were detected for the first time in 5 patients during the second and third postinjury weeks. One adolescent still had a blood blister on day 34. There were no additional examinations of this group of adolescents.

Erythema

The redness of the tissues that is created by capillary congestion (erythema) constitutes a nonspecific finding. Therefore, erythema is not included as a variable in "Results" because of its uncertain clinical significance.

Hematomas

What initially seemed to be a well-defined, localized collection of blood (hematoma) dramatically changed during a relatively short period as the blood disseminated into the surrounding tissues (Table 1). At that point, they were considered to be submucosal hemorrhages.

Petechiae

Sixty-nine (60%) of the 113 prepubertal girls had a pinpoint, nonraised, perfectly round, purplish red spot (petechia) on their hymenal membrane at the time of their initial examination (Table 1). No petechiae were detected beyond 48 hours in any of the prepubertal girls. Sixty-five (50%) of the 126 adolescents had petechiae on their hymens at the time of their initial evaluation (Table 1). No petechiae were identified in any of these pubertal girls after 72 hours.

Submucosal Hemorrhages

Submucosal hemorrhages were discovered in 51 (45%) of the 113 prepubertal girls and in 67 (53%) of the 126 pubertal adolescents. Evidence of this bleeding into the areolar tissue beneath the mucosal membrane was found primarily in the posterior quadrants of the hymen in both age groups. The depth of discoloration of a submucosal hemorrhage and its relative size in relationship to the surrounding tissue was used in classifying them as mild, moderate, or marked. Each lesion was individually tracked, and the disappearance day was recorded. The more severe hemorrhages gradually evolved into either a moderate or mild form before completely disappearing (Table 1).

Hymenal Lacerations

The 40 hymenal lacerations that were observed in the 113 prepubertal girls were reevaluated a total of 60 times. The 80 hymenal lacerations that were identified in the 126 pubertal adolescents were reexamined a total of 93 times. The locations of these lacerations were recorded in relationship to the face of a clock as though the patient were in a supine position. As the hymenal lacerations healed, several changes took place. These included variations in both the depth and the configuration of the laceration.

The location of the hymenal lacerations varied somewhat by age (Table 2). Both groups of patients had significantly more ($P < .01$) lacerations on the posterior half of their hymenal rim than on the anterior portion of this membrane. Of the posterior rim lacerations, 75% of the prepubertal girls' lacerations were in or close to the midline, whereas only 29% of the adolescents' lacerations were found at this same area ($P < .001$). Conversely, the older patients had a greater percentage of lacerations along the lateral hymenal rim at the 3 o'clock and 9 o'clock locations ($P < .05$) than the younger girls.

Depth of the Healing Hymenal Lacerations

Prepubertal Girls

The depth of the hymenal lacerations in the prepubertal girls ranged from superficial tears to transections that extended into the fossa navicularis and beyond

TABLE 3 Depth of 40 Hymenal Lacerations on the Final Follow-up: Prepubertal Girls

Classification	Contusion, <i>n</i> (%)	Superficial, <i>n</i> (%)	Intermediate, <i>n</i> (%)	Deep, <i>n</i> (%)	Transection, <i>n</i> (%)	Transection With an Extension, <i>n</i> (%)	Undetected or Healed, <i>n</i> (%)
2: Superficial (4/5 F/U)	1 (20)	1 (20)	1 (20)				2 (40)
3: Intermediate (3/6 F/U)		2 (33)	1 (17)		1 (17)		2 (33)
4: Deep (12/21 F/U)		2 (10)	3 (14)	13 (61)	2 (10)	1 (5)	
5: Transection (4/7 F/U)			1 (14)	2 (29)	3 (43)		1 (14)
6: Transection with an extension (17/31 F/U)				7 (23)	14 (45)	9 (29)	1 (3)

F/U indicates number of acute lacerations per number of follow-up examinations.

(Table 3). As they healed, the apparent depth of a number of the lacerations changed. Whereas most of the lacerations took on a more superficial appearance, others became deeper in appearance as the swelling of the surrounding tissues receded. Sixty-eight percent of transections with an extension evolved into either transections without an extension or into deep-appearing lacerations as they healed. The reverse of this trend was also observed. Fifteen percent of deep lacerations turned out to be transections in which all evidence of a hymenal rim at the base of the laceration disappeared as the swelling of the tissues subsided.

The case of an 8-month-old is an example of the healing process that was observed in several of the prepubertal girls. Her hymenal (Fig 1, arrow), fossa navicularis, and posterior fourchette lacerations, as seen on the third day after the assault, dramatically changed in appearance during the subsequent month. By the 28th day, the posterior rim of her hymen appears smooth and relatively wide (Fig 2). Her fossa navicularis and posterior fourchette injuries have disappeared, leaving only a collection of small blood vessels (neovascularity) at the site of her injuries.

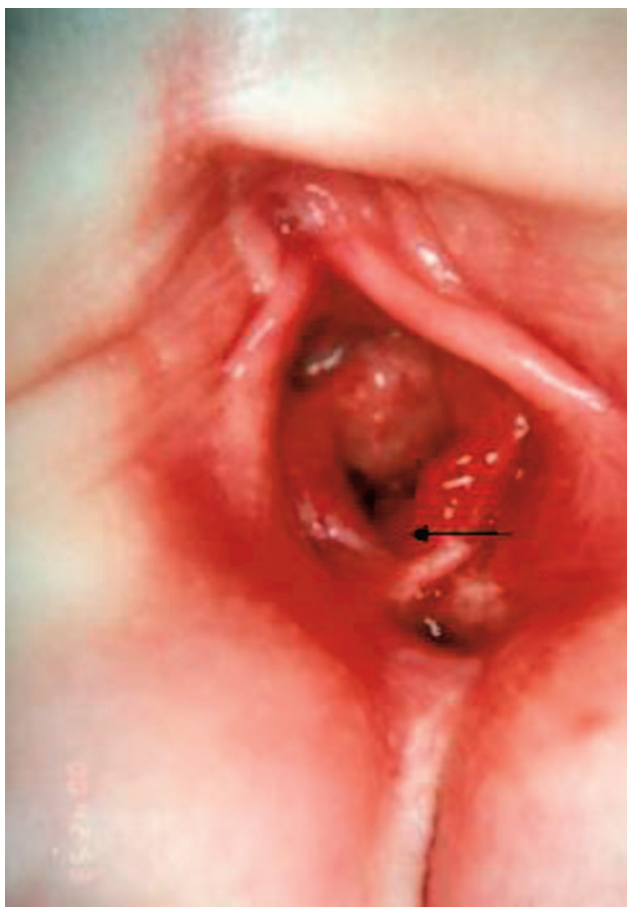


FIGURE 1
Case 1: An 8-month-old, assaulted 3 days before, has a V-shaped deep hymenal laceration at the 6 o'clock position (arrow) and fossa navicularis and posterior fourchette lacerations. The patient was examined by supine, labial traction method.

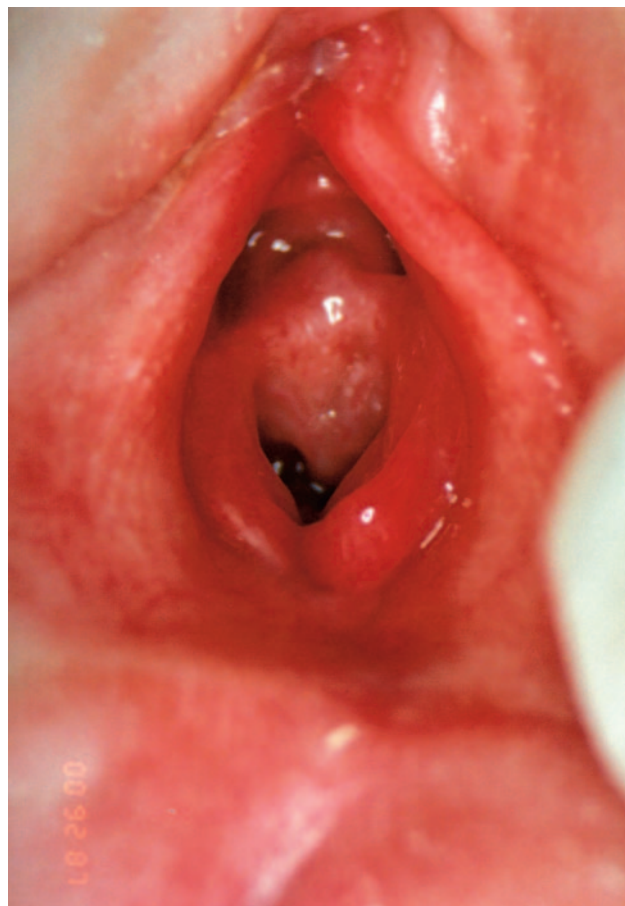


FIGURE 2
Case 1: Twenty-four days after assault. The hymenal edge has smoothed off, leaving a relatively wide rim. Neovascular formation is present at the site of fossa navicularis and posterior fourchette injuries. Note 2 longitudinal intravaginal ridges on either side of the orifice immediately behind the hymenal membrane. The patient was examined with the supine, labial traction method.

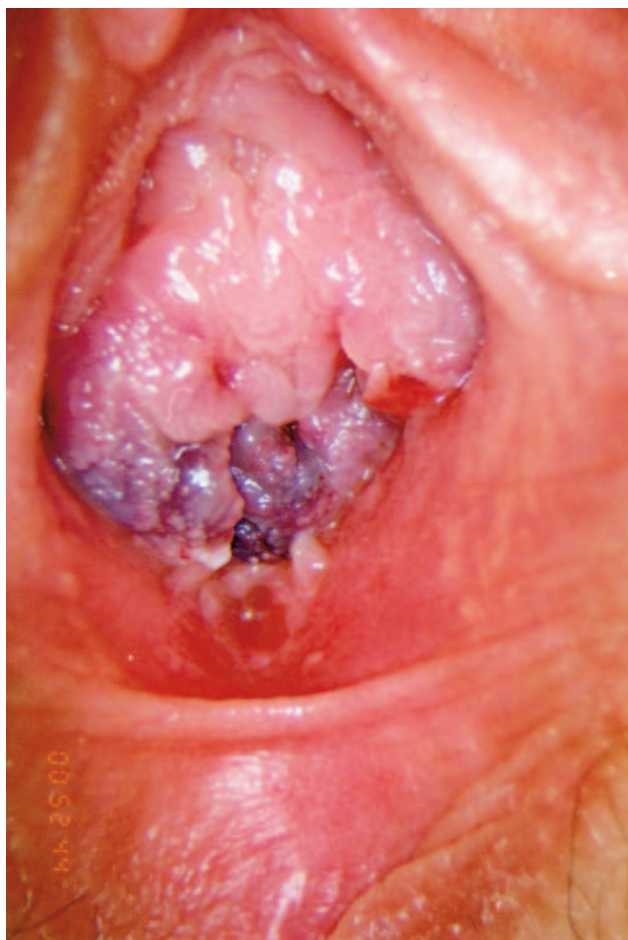Pubertal Adolescents

The recorded depth of the hymenal lacerations also changed in many of the older adolescents as their wounds healed (Table 4). As the swelling of the tissues subsided and the submucosal hemorrhages disappeared, a number of the wounds took on a shallower appearance. In contrast, this same phenomenon also exposed deeper injuries. Lacerations in 2 adolescents were originally classified as deep. As the swelling of their tissues subsided, the lacerations had to be reclassified as transections. During a follow-up examination, evidence of a laceration was no longer detectable in 3 adolescents because of the redundancy of their hymenal tissues.

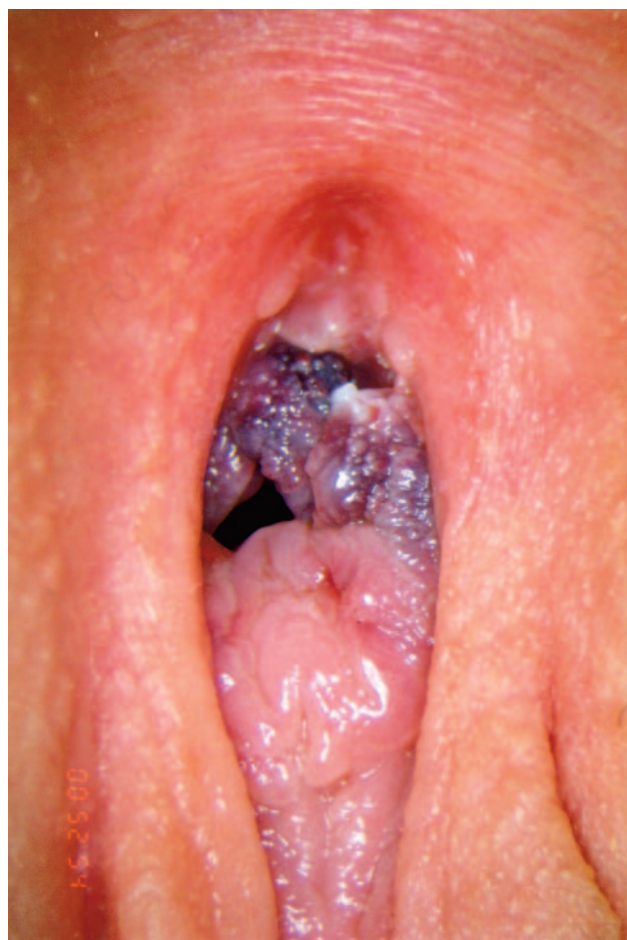The case of a 14-year-old adolescent exemplifies how the presence of edema and submucosal hemorrhage can effect the findings (Figs 3 and 4). This girl was sexually assaulted 12 hours before her initial examination. By the fourth day after the assault, the swelling had receded and most of the submucosal hemorrhage had disap-

TABLE 4 Depth of 80 Hymenal Lacerations on the Final Follow-up: Pubertal Adolescents

Classification	Superficial, n (%)	Intermediate, n (%)	Deep, n (%)	Transection, n (%)	Transection With an Extension, n (%)	Undetected or Healed, n (%)
2: Superficial (13/14 F/U)	8 (57)	3 (21)	1 (7)			2 (15)
3: Intermediate (9/12 F/U)	3 (25)	9 (75)				
4: Deep (22/24 F/U)		5 (21)	15 (63)	2 (8)		1 (4)
5: Transection (23/26 F/U)	2 (8)	3 (12)	12 (46)	7 (27)		2 (8)
6: Transection with an extension (13/17 F/U)		2 (12)	3 (18)	10 (59)	2 (12)	

**FIGURE 3**

Case 2: A 14-year-old 12 hours after assault. Marked submucosal hemorrhages are present on the lower half of the hymenal membrane. Note the fresh-cut edge of a hymenal laceration at the 3 o'clock position. The patient was examined with the supine, labial traction method.

**FIGURE 4**

Case 2: Twelve hours after assault. The submucosal hemorrhage seems to involve the entire posterior half of the hymenal membrane. The patient was examined with the prone, knee-to-chest position method.

peared (Figs 5 and 6). In the prone, knee-to-chest position (Fig 6), the multiple lacerations of her hymen became apparent and her hymenal orifice took on a "starburst" appearance. On the 16th day after injury (Fig 7), her evaluation by the supine, labial traction technique revealed only a single "cleft" at the 8 o'clock position. As she was repositioned into the prone, knee-to-chest position, evidence of her multiple lacerations once again became apparent (Fig 8).

Changes in Configuration of a Healing Hymenal Laceration

Prepubertal Girls

The most common configuration of the acute hymenal lacerations in the prepubertal age group was a V-shaped laceration (39%). Of the 40 acute lacerations that were identified in the prepubertal girls, 21% were cleft-like. On healing, the proportion of clefts decreased to 10%. The percentage of V-shaped lacerations dropped from 39% to 18%. The smoother, U-shaped configurations increased from 21% to 46% as they healed. The

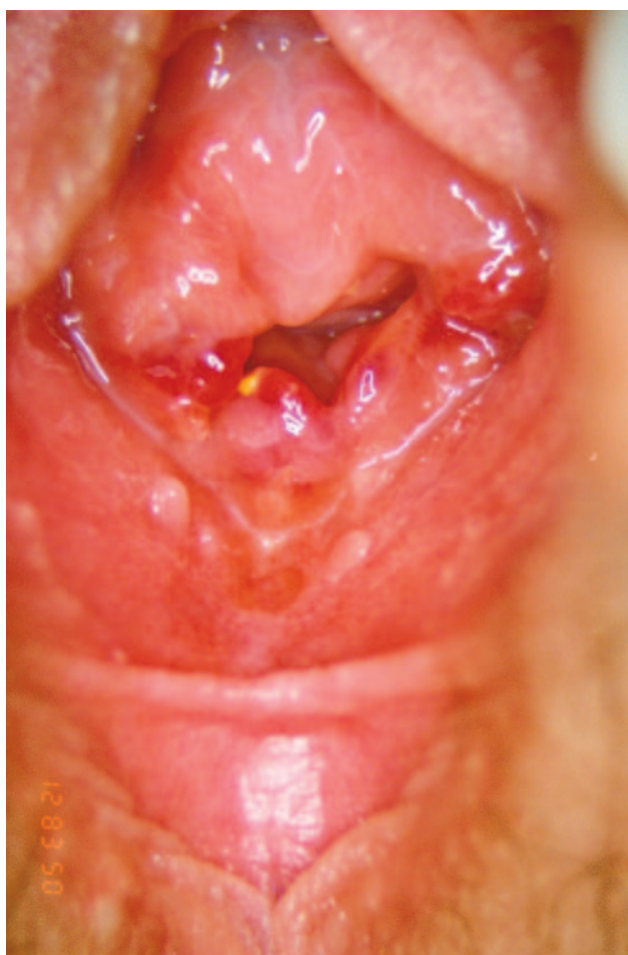

FIGURE 5

Case 2: Four days after assault. The major portion of the submucosal hemorrhage has resolved, exposing evidence of hymenal lacerations at the 3 o'clock and 8 o'clock positions. The patient was examined with the supine, labial traction method.

broad-based, U-shaped lacerations increased slightly from 18% to 23%. On healing, 3% of the prepubertal girls had perfectly smooth, wide hymenal rims that revealed no evidence of the previous trauma. The case of the 9-year-old whose father confessed to having sexually assaulted his daughter 3 days before (Fig 9) is an example of a V-shaped laceration's smoothing off and taking on a smoother, "key-hole" type of appearance (Fig 10) by the 19th day after assault.

Pubertal Adolescents

The most common configuration of the acute hymenal laceration in the adolescent was also V-shaped (48%). Of the 80 acute lacerations that were identified in the adolescent girls, 28% were cleft-like. The percentage of these cleft-like lacerations decreased to 22% as they healed. The percentage of V-shaped lacerations decreased from 48% to 24% over time. The smoother, narrow, U-shaped configurations increased from 24% to 34%, whereas the broad-based, U-shaped-appearing lacerations increased significantly from 1% to 20% ($P <$

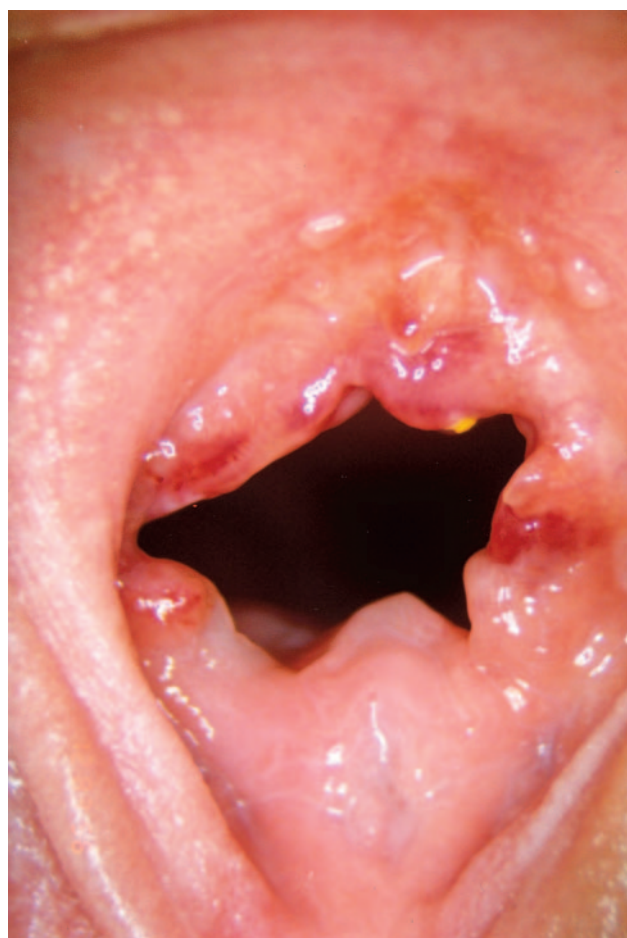

FIGURE 6

Case 2: Four days after assault. The lacerations at the 3 o'clock and 9 o'clock positions (supine) become more evident as the hymenal orifice opens during the prone, knee-to-chest position method.

.05). Three percent of the hymenal lacerations could no longer be identified during a follow-up examination.

Outcome of the Hymenal Lacerations

The healing process of a hymenal injury varied with the extent of the injury. Evidence of a "recent" injury faded rapidly. This included the disappearance of edema, petechiae, submucosal hemorrhages, and fresh-cut surfaces. Beyond this initial period, the lacerations continued to undergo changes in both depth and configuration for up to 3 and 4 weeks. The sites of the healed lacerations varied in smoothness, continuity, and width (Tables 5 and 6). No scar tissue was identified on the hymen of any of the girls.

Prepubertal Girls

No evidence of an acute hymenal laceration was present by the end of the first week in 2 of the 4 prepubertal girls who were examined during that period. By 10 days, 9 (82%) of 11 patients no longer had signs of an acute injury. Except for the 1 girl with the blood blister, all evidence of an acute hymenal injury had

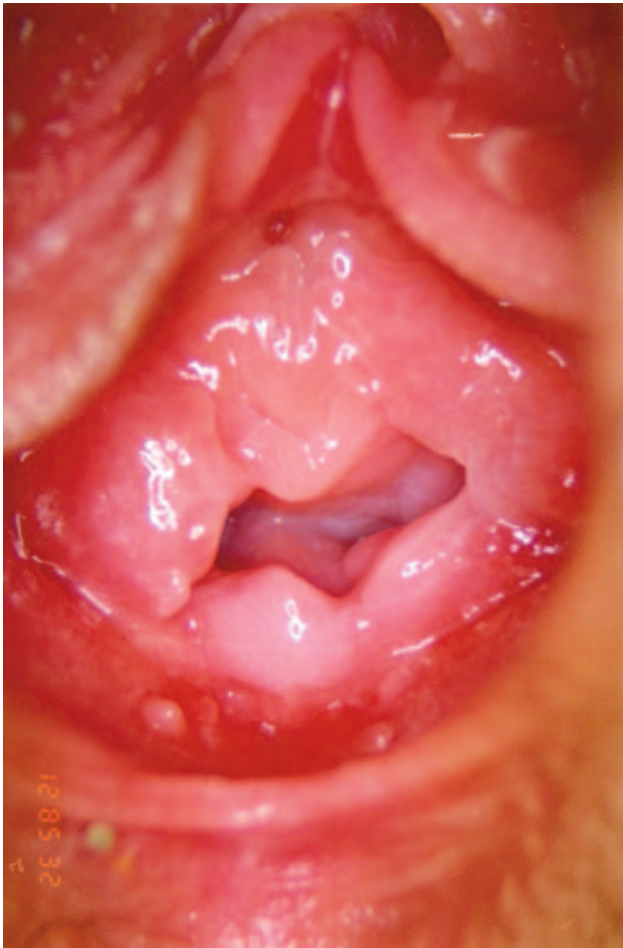

FIGURE 7

Case 2: Sixteen days after assault. Evidence of the acute injuries has disappeared, leaving only a cleft at the 8 o'clock position. The patient was examined with the supine, labial traction method.

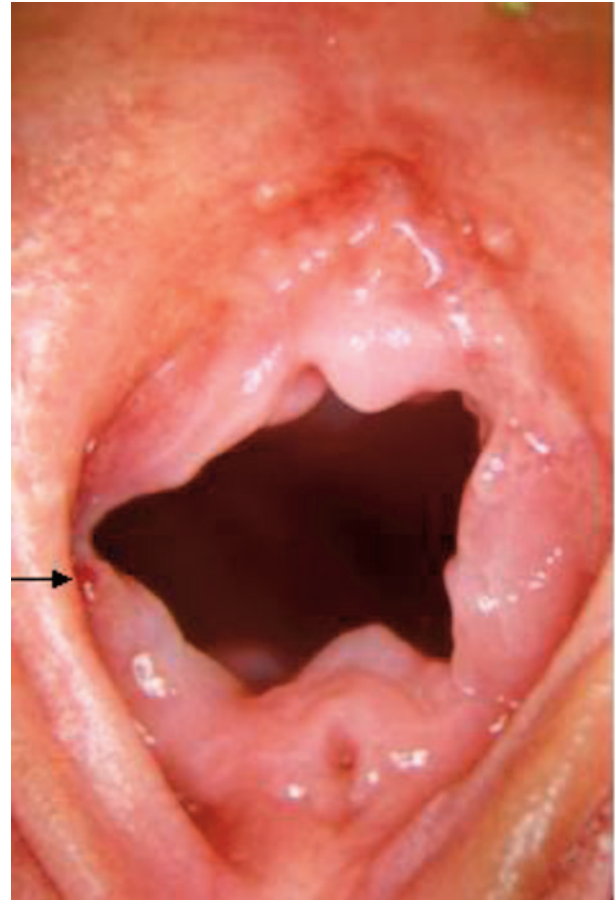

FIGURE 8

Case 2: Sixteen days after assault. The "starburst" appearance created by the multiple lacerations of the hymenal rim become apparent during this examination method. A small blood blister is present at the 2:30 position supine (arrow). The patient was examined with the prone, knee-to-chest position method.

disappeared by the 16th (22 of 22) day after injury. No change in either the depth or the configuration of a healing laceration was observed beyond 30 days.

The appearance of the healed lacerations on the hymenal rims of 2 prepubertal girls remained constant during the 2 and 3 years they were followed. Evidence of a laceration in 2 other prepubertal girls disappeared into the folds of their estrogenized hymens when they entered into puberty.

The final outcome of the prepubertal girl's hymenal laceration was dictated by the extent of the injury (Table 5). When the results of the superficial, intermediate, and deep lacerations were combined, 75% (15 of 20) of the prepubertal girls had smooth hymenal rims with no disruption in contour ("continuous"). Of those who had sustained a transection or a transection with an extension, 17% (3 of 18) had a smooth rim, whereas 22% (4 of 18) had a continuous-appearing hymenal membrane on healing. The hymenal rim widths measured <1 mm in 28% (5 of 18) of the girls who had sustained either a transection or a transection with an extension. Hymenal

rim width measurements were not obtained in the girls with the less severe injuries.

Pubertal Adolescents

Evidence of a recent injury disappeared in the adolescents at approximately the same rate as their prepubertal counterparts. In the first 7 days, 5 (56%) of 9 adolescents no longer had signs of edema, erythema, submucosal hemorrhage, or fresh-cut surfaces. At 10 days, 9 of 9 still had evidence of an acute injury. By 2 weeks, 90% (19 of 21) of the lacerations appeared healed. By 3 weeks, only those with blood blisters still had signs of a recent injury. None of the adolescents were followed for >90 days.

Similar to the findings in the prepubertal girls, the final outcome of an adolescent's hymenal laceration was determined by the extent of the injury (Table 6). When the results of superficial, intermediate, and deep lacerations were combined, 59% (24 of 41) of the hymenal rims had a normal, scalloped appearance and 88% (30 of 34) revealed no disruption in continuity. Thirty-eight percent of the hymenal rims of pubertal adolescents who

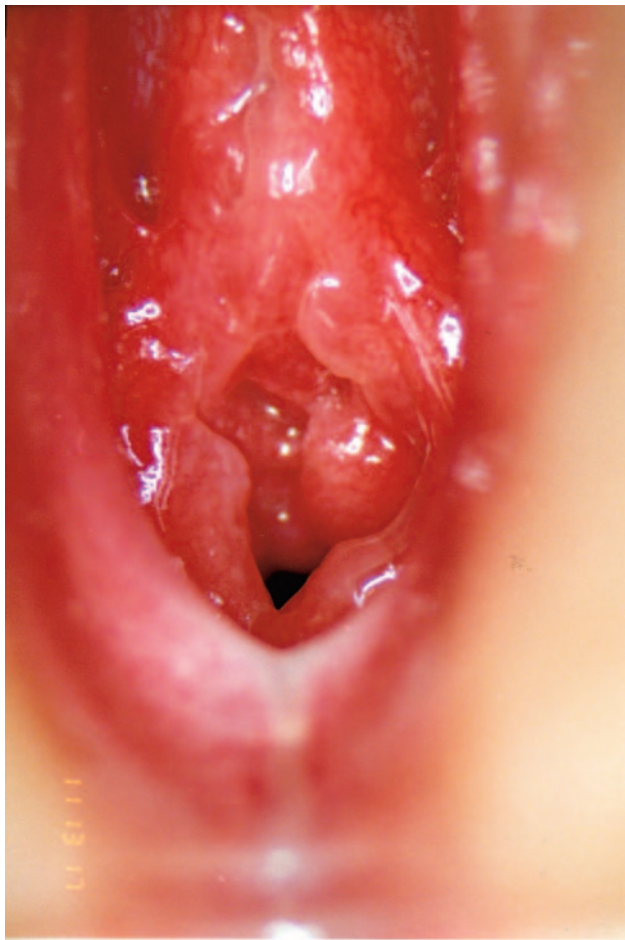

FIGURE 9

Case 3: A 9-year-old assaulted 3 days before. Deep V-shaped laceration is present at the 6:30 position. Fresh-cut edges of the wound are still visible. The patient was examined with the supine, labial traction method.

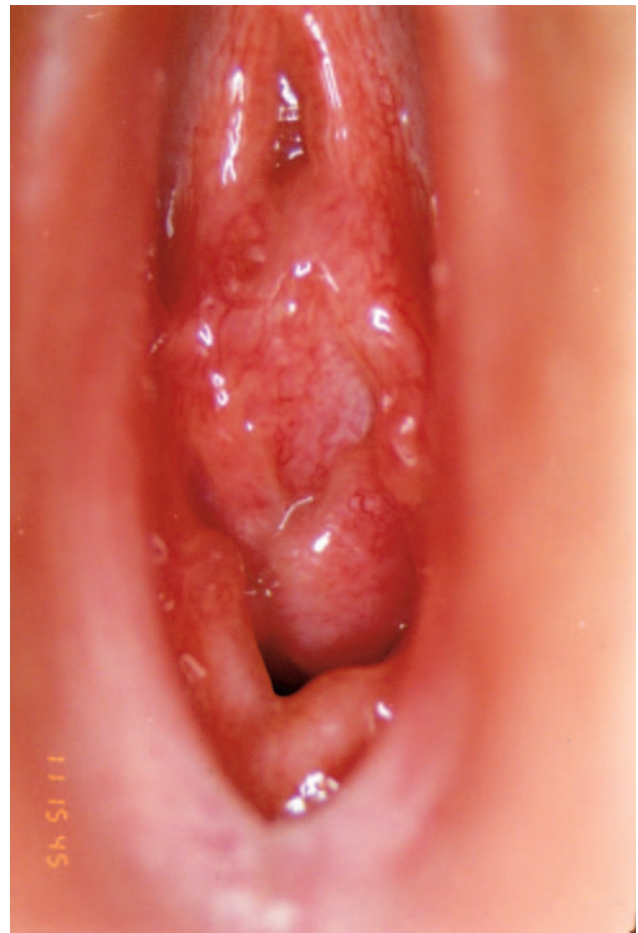

FIGURE 10

Case 3: Nineteen days after assault. The V-shaped laceration has smoothed off, leaving a "keyhole-type" appearance. Mounds on either side of the orifice formed by 2 intravaginal longitudinal ridge attachments. The patient was examined with the supine, labial traction method.

sustained either a transection or a transection with an extension had a narrow but normal, scalloped appearance. Fifty-nine percent (17 of 29) revealed no disruption of the contour of their hymenal membrane. Eighty-seven percent (21 of 24) did have rims that measured <1 mm in width. No hymenal scars were identified in any of the prepubertal or adolescent girls.

DISCUSSION

Many of the findings in this study are similar to those in other reports on hymenal injuries. The majority of the hymenal lacerations in this study did smooth off over time, as previously reported by McCann et al.² The variety in the configuration of the healed lacerations described by Kerns et al¹³ is similar to those observed in this report. Although the terminology differed, the outcome of the 37 girls with hymenal injuries in the report by Heppenstall-Heger et al³ seems to be similar to that found in this study. One difference in the results of their study with ours is the location of the hymenal lacerations. Heppenstall-Heger et al reported, "All tears oc-

curred in the posterior 180 degrees, between 4 and 8 o'clock, except for 1 accidental avulsion injury." We identified hymenal lacerations at all locations on the hymenal rim in both the prepubertal and the adolescent girls (Table 2). One possible explanation is the type of examination methods used. Several of the anterior and lateral lacerations that we identified were detected only during the prone, knee-to-chest position. Although Heppenstall-Heger et al reported that they used this method, it was used only "when abnormalities were noted."

The observation by Berenson et al¹⁴ of a hymenal rim width of <1 mm in their 3- to 8-year-old girls who had "a history of penetration" was consistent with the outcome of some but not all of the girls in this study. In our report, 13 (72%) of 18 of the prepubertal girls who had sustained a laceration that either transected the hymen or extended through the hymenal attachment and into the surrounding tissues still had a hymenal rim width of >1 mm on healing (Table 5). This phenomenon in the prepubertal girl was attributed to the development of a very thin, delicate membrane that appeared at the base

TABLE 5 Healed Hymenal Rim Findings By Depth of Laceration: Prepubertal Girls

Depth	Yes, n (%)	No, n (%)	UTD, n (%)
Superficial (n = 4)			
Smooth appearance	2 (50)	1 (25)	1 (25)
Continuous	2 (50)	1 (25)	1 (25)
Delicate	1 (25)	2 (50)	1 (25)
<1 mm in width	1 (25)		3 (75)
Intermediate (n = 4)			
Smooth appearance	4 (100)		
Continuous	4 (100)		
Delicate	2 (50)	2 (50)	
<1 mm in width		1 (25)	3 (75)
Deep (n = 11)			
Smooth appearance	9 (82)	2 (18)	
Continuous	9 (82)	2 (18)	
Delicate	4 (36)	7 (64)	
<1 mm in width		1 (9)	10 (91)
Transection (n = 4)			
Smooth appearance	2 (50)	1 (25)	1 (25)
Continuous	2 (50)	1 (25)	1 (25)
Delicate	1 (25)	2 (50)	1 (25)
<1 mm in width	1 (25)	1 (25)	2 (50)
Transection/extension (n = 16)			
Smooth appearance	1 (6)	14 (88)	1 (6)
Continuous	2 (13)	13 (81)	1 (6)
Delicate	1 (6)	15 (94)	
<1 mm in width	4 (25)	12 (75)	

UTD indicates unable to determine for a variety of reasons.

of the laceration as the healing took place. In the adolescents, the width of the healed hymenal rim was >1 mm in 13% after the healing of these 2 deeper types of lacerations (Table 6).

The commentary by Adams¹⁵ on the likelihood of a finding being normal if there is a “continuity of the hymenal rim” seems reasonable. Unfortunately, her comment did not take into account the remarkable healing process of the injured hymenal membrane. In our study, the majority of the prepubertal girls still had a smooth edge and continuity of the hymenal rim after the healing of all but the most severe lacerations. The results were similar in the adolescent population. Although there was a significant disruption of the integrity of the hymenal membrane in both groups after the deeper transections that extended into the surrounding tissues, the hymenal tissue still healed remarkably well (Tables 5 and 6).

Once we completed the analysis of the data, it became apparent that there was neither a “time sequence” nor a “pattern” in the healing process that could be used to determine the age of an injury. The time sequence was determined by the severity of the injury, whereas the patterns proved to be too nonspecific to use in the determination of the age of an injury. Even the lacerations showed no consistency in the healing process as they became shallower in appearance and their sharp edges smoothed off. However, there were 2 “markers” in the

TABLE 6 Healed Hymenal Rim Findings by Depth of Laceration: Pubertal Girls

Depth	Yes, n (%)	No, n (%)	UTD, n (%)
Superficial (n = 13)			
Normal scalloped appearance	8 (62)	4 (31)	1 (8)
Continuous	11 (50)	1 (8)	1 (8)
<1 mm in width	3 (23)	6 (46)	4 (31)
Intermediate (n = 9)			
Normal scalloped appearance	6 (67)	2 (22)	1 (11)
Continuous	7 (78)	1 (11)	1 (50)
<1 mm in width	3 (33)	3 (33)	3 (33)
Deep (n = 20)			
Normal scalloped appearance	10 (46)	11 (50)	1 (4)
Continuous	12 (60)	2 (9)	5 (23)
<1 mm in width	10 (46)	6 (27)	6 (27)
Transection (n = 23)			
Normal scalloped appearance	8 (35)	12 (52)	3 (13)
Continuous	11 (48)	8 (35)	4 (17)
<1 mm in width	14 (61)	1 (4)	8 (45)
Transection/extension (n = 13)			
Normal scalloped appearance	4 (31)	8 (62)	1 (8)
Continuous	6 (46)	5 (39)	2 (15)
<1 mm in width	7 (54)	2 (15)	4 (31)

UTD indicates unable to determine for a variety of reasons.

healing process that provided a method for approximating the age of an injury. One marker was the presence of petechiae, and the other was the presence of a blood blister. A petechia was an indication that the injury had occurred within the past 48 to 72 hours. None of these pinhead-sized lesions was identified in any of the prepubertal girls beyond 48 hours or in the adolescent girls after 72 hours. What initially seemed to be exceptions to this rapid resolution of a petechia turned out to be small vascular anomalies that were still present weeks after an injury.

The second marker, at the other end of the spectrum, was the presence of a blood blister (Fig 8). These small, blood-filled vesicular lesions, which frequently appeared for the first time during a follow-up examination, indicated that an injury had occurred sometime in the past month. This marker was particularly helpful in the adolescent cases when all other signs of an acute injury had disappeared.

Completion of the healing process was defined by the disappearance of the signs of an acute injury and the cessation of changes in the depth and the configuration of a laceration. Whereas most signs of an acute injury were gone within 7 to 10 days, the changes in the depth and the configuration of a laceration continued for up to 3 weeks in the prepubertal girl and 4 weeks in the adolescent girl.

In this study, the findings that were created by a hymenal laceration in 2 prepubertal girls remained unchanged until they reached puberty. The findings in 2 other girls disappeared into the folds of their estrogenized hymens as they entered into puberty. None of the

adolescents was followed long enough to determine how their findings might have changed over time. The data from this study did not reveal any difference in the healing process between the prepubertal and pubertal girls. The nonhymenal genital injuries data on the healing process and their outcome in this population of girls will be presented in a companion report.

CONCLUSIONS

The hymenal injuries in these prepubertal and adolescent girls all healed rapidly and frequently left little or no evidence of the previous trauma. The rapid resolution of the petechiae along with the persistence of blood blisters did provide markers for approximating the age of an injury. The multiple locations of the lacerations on the hymenal rim are a reminder of the importance of the multimethod approach during these examinations. Although the outcome and the final appearance of a hymenal laceration depended on its severity, the smoothness and the persistent continuity of a hymenal rim after all but the most severe lacerations should prove to be reassuring to the victim and her family. No scar tissue was identified on the hymen in any of the patients. These findings reaffirm the remarkably complex healing process that occurs after a hymenal injury. These data heighten the examiner's need to exercise caution before calling a finding "normal, without evidence of a previous injury."

APPENDIX: GLOSSARY OF TERMS

1. Cleft: An angular defect on the edge of the hymen whose edges are closely approximated. The defect may extend to the muscular attachment of the hymen.
2. Concavity: A curved or hollowed U-shaped depression of the edge of the hymenal membrane.
3. Notch: A V-shaped indentation or defect on the edge of the hymenal membrane that may extend to the muscular attachment of the hymen.
4. Hymenal tear/laceration: A defect (injury) in the hymenal membrane caused by a blunt object that has ripped or pulled apart (rendered) the tissue.
5. Superficial partial tear of the hymenal membrane: A laceration or tear of the hymenal membrane that extends less than halfway through the width of the membrane.
6. Intermediate partial tear of the hymenal membrane: A laceration or tear of the hymenal membrane that extends halfway through the width of the membrane.
7. Deep partial tear of the hymenal membrane: A laceration or tear of the hymenal membrane that ex-

tends more than halfway through the width of the membrane.

8. Complete tear or transection of the hymen: A laceration or tear of the hymenal membrane that extends through the entire width of the membrane to its attachment.
9. Transection of the hymen with an extension: A laceration or tear of the hymenal membrane that extends through the attachment and into the surrounding tissues.
10. Laceration: A defect of the tissues caused by a ripping or pulling apart (rendering). The wound may contain bridging structures.
11. Incision: A wound created by a sharp instrument whose edges are well defined. The wound contains no bridging structures.

ACKNOWLEDGMENTS

This study was supported in part from the Lucile Packard Foundation; the Kenneth Jonsson Family Foundation; and the Children's Miracle Network through the Department of Pediatrics, University of California, Davis.

We thank the following individuals for their participation in this multicenter, collaborative research project: David Kerns, MD, Valley Medical Center, San Jose, California; Marilyn Kaufhold, MD, San Diego Children's Hospital; Mary Ritter, CHA, Valley Medical Center, San Jose, California; Joan Voris, MD, University Hospital and Medical Center, Fresno, California; Terrence Donald, MD, Women's and Children's Hospital, North Adelaide, Australia; Martin Finkel, DO, University of Medicine and Dentistry of New Jersey, Stratford, New Jersey; Lori Frasier, MD, University Physicians-Green Meadows, Columbia, Missouri; Wendy Gladstone, MD, Exeter Pediatric Associates, Exeter, New Hampshire; Penny Grant, Child Abuse Network, Tulsa, Oklahoma; Nancy Harper, MD, Naval Medical Center Portsmouth, Virginia; Roberta Hibbard, MD, Indiana University School of Medicine, Indianapolis, Indiana; Ralph Hicks, MD, Wright State University, Dayton, Ohio; Margie Hogan, MD, Hennepin County Medical Center, Minneapolis, Minnesota; Michael Jordan, MD, Medical Office Building, Newark, New York; Michael Knappman, PA-C, Redwood Children's Center, Santa Rosa, California; Kathe Krale, RN, MSN, CPNP, Children's Mercy Hospital, Kansas City, Missouri; Susan Murawski, MS, ARNP, CPNP, Southwest Florida Children's Fund, Fort Myers, Florida; Vincent Palusci, MD, Michigan State University College of Human Medicine, Grand Rapids, Michigan; Andrew Sirotnak, MD, Children's Hospital, Denver, Colorado; Naomi Sugar, MD, HCSATS, Seattle, Washington; Andi Taroli, MD, Children's Advocacy Center, Scranton, Pennsylvania; Danny Waldrop, MD, Geisinger Medical

Center, Danville, Pennsylvania; J.M. Whitworth, MD, Florida Children's Fund, Jacksonville, Florida.

Special thanks go to Ana Ross, PA-C, for assistance in reviewing the medical charts of the UCDCM patients; to Stephen Boos, MD, Lieutenant Colonel, United States Air Force Medical Corps, for review of the manuscript; and to Lieschen Trelford for assistance with the myriad of tasks connected to the preparation of this manuscript.

REFERENCES

1. Finkel MA. Anogenital trauma in sexually abused children. *Pediatrics*. 1989;84:317-322
2. McCann J, Voris J, Simon M. Genital injuries resulting from sexual abuse: a longitudinal study. *Pediatrics*. 1992;89:307-317
3. Heppenstall-Heger A, McConnel G, Ticson L, Guerra L, Lister J, Zaragoza T. Healing patterns in anogenital injuries: a longitudinal study of injuries associated with sexual abuse, accidental injuries, or genital surgery in the preadolescent child. *Pediatrics*. 2003;112:829-837
4. Pokorny SF. Configuration of the prepubertal hymen. *Am J Obstet Gynecol*. 1987;157:950-956
5. Muram D. Child sexual abuse: genital tract findings in prepubertal girls. I. The unaided medical examination. *Am J Obstet Gynecol*. 1989;160:328-332
6. McCann J, Wells R, Simon M, Voris J. Genital findings in prepubertal girls selected for non-abuse: a descriptive study. *Pediatrics*. 1990;86:428-439
7. Berenson A, Heger A, Andrews S. Appearance of the hymen in newborns. *Pediatrics*. 1991;87:458-465
8. Berenson A, Heger A, Hayes J, Bailey R, Emans SJ. Appearance of the hymen in prepubertal girls. *Pediatrics*. 1992;89:387-394
9. Berenson A. Appearance of the hymen at birth and one year of age: a longitudinal study. *Pediatrics*. 1993;91:820-825
10. Myhre AK, Berntzen K, Bratlid D. Genital anatomy in non-abused preschool girls. *Acta Paediatr*. 2003;92:1453-1462
11. Heger A, Ticson L, Velasquez O, Bernier R. Children referred for possible sexual abuse: a comparison of clinical history and medical findings in 2384 children. *Child Abuse Negl*. 2002;26:645-659
12. Heger A, Ticson L, Guerra L, Lister J, Zaragoza T, McConnell G. Appearance of the genitalia in girls selected for non-abuse: a review of hymenal morphology and non-specific findings. *J Pediatr Adolesc Gynecol*. 2002;15:27-35
13. Kerns DL, Ritter ML, Thomas RG. Concave hymenal variations in suspected child sexual abuse victims. *Pediatrics*. 1992;90:265-272
14. Berenson AB, Chacko MR, Wiemann CM, Mishaw CO, Friedrich WN, Grady JJ. Use of hymenal measurements in the diagnosis of previous penetration. *Pediatrics*. 2002;109:228-235
15. Adams J. Normal studies are essential for objective medical evaluation of children who may have been sexually abused. *Acta Paediatr*. 2003;92:1378-1380
16. Berenson A, Chacko M, Wiemann CM, Mishaw CO, Friedrich WN, Grady JJ. A case-control study of anatomic changes resulting from sexual abuse. *Am J Obstet Gynecol*. 2000;182:828-835
17. Landis JR, Koch GG. The measurements of observer agreement for categorical data. *Biometrics*. 1977;33:159-174
18. Fleiss JL. *Statistical Methods for Rates and Proportions*. 2nd ed. Chicago, IL: John Wiley & Sons; 1981
19. Bays J, Chewning M, Keltner L, Stewell R, Steinberg M, Thomas P. Changes in hymenal anatomy during examination of prepubertal girls for possible sexual abuse. *Adolesc Pediatr Gynecol*. 1990;3:34-46
20. McCann J, Voris J, Simon M, Wells R. Comparison of genital examination techniques in prepubertal girls. *Pediatrics*. 1990;85:182-187

Healing of Hymenal Injuries in Prepubertal and Adolescent Girls: A Descriptive Study

John McCann, Sheridan Miyamoto, Cathy Boyle and Kristen Rogers
Pediatrics 2007;119:e1094-e1106; originally published online Apr 9, 2007;
DOI: 10.1542/peds.2006-0964

Updated Information & Services	including high-resolution figures, can be found at: http://www.pediatrics.org/cgi/content/full/119/5/e1094
References	This article cites 19 articles, 10 of which you can access for free at: http://www.pediatrics.org/cgi/content/full/119/5/e1094#BIBL
Post-Publication Peer Reviews (P³Rs)	One P ³ R has been posted to this article: http://www.pediatrics.org/cgi/eletters/119/5/e1094
Subspecialty Collections	This article, along with others on similar topics, appears in the following collection(s): Adolescent Medicine http://www.pediatrics.org/cgi/collection/adolescent_medicine
Permissions & Licensing	Information about reproducing this article in parts (figures, tables) or in its entirety can be found online at: http://www.pediatrics.org/misc/Permissions.shtml
Reprints	Information about ordering reprints can be found online: http://www.pediatrics.org/misc/reprints.shtml

American Academy of Pediatrics

DEDICATED TO THE HEALTH OF ALL CHILDREN™

