

# GANGLION CYST ULTRASOUND PROTOCOL (UEXTR, UEXTL OR UEXTB)

**PATIENT PREP:** No prep

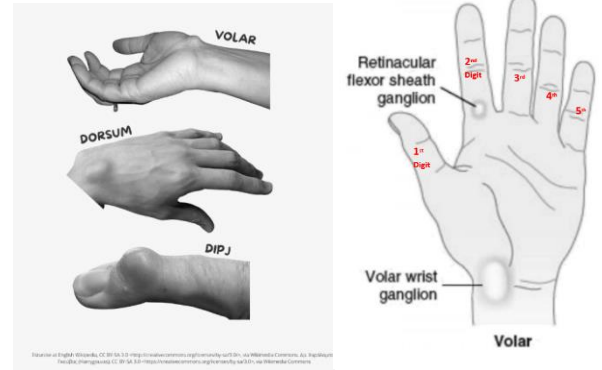
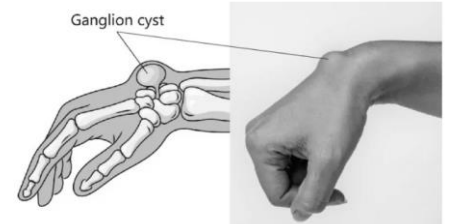
**LOCATION:** Hand, wrist or foot

A ganglion cyst is a benign fluid-filled lump under the skin.

It is most commonly located over a joint or in a tendon in the hand or wrist but can also occur on the foot.

**LOCATIONS OF GANGLION CYSTS:**

- **Volar** – palm side of wrist
- **Dorsal** - top of the wrist
- **Retinacular** – hand, usually base of the finger
- **Distal Interphalangeal (DIP) Joint** – first joint of the fingers, just before the fingernail starts.



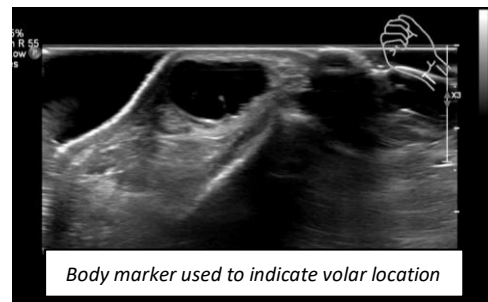
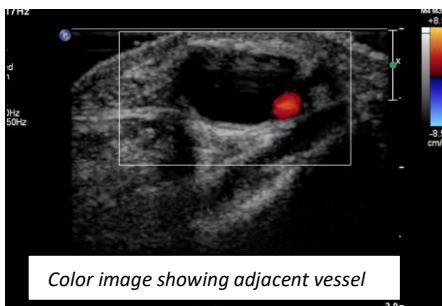
## IMAGES TO OBTAIN

*Clearly label all images with the anatomic location and use body marker when able.*

**TECHNIQUE:** Use standoff pad if too superficial or if difficult to keep probe on skin.

**FOCUSED IMAGES OF AREA OF CONCERN:**

- Transverse
  - Cine clip, superior to inferior
  - 2D image with and without measurements
  - Color image showing cyst and any adjacent blood vessels.
- Sagittal
  - Cine clip, superior medial to lateral
  - 2D image with and without measurements



### Ganglion Cyst Ultrasound Protocol History

	Date	Changes made	By whom
Created	1/22/2024		Renee Betit Fitzgerald
Approved	1/22/2024		Manjiri Dighe