

PROSTATE ULTRASOUND PROTOCOL

BILLING CODE: UPROS

Used for indications of infection or abscess. This is not a screening for malignancy. These screenings are done by the urology department.

PATIENT PREP: Bladder should be emptied immediately prior to exam.

EQUIPMENT: Endocavitary transducer, C10-3 frequency or higher.

GENERAL GUIDELINES: Images to be obtained from a transrectal approach. The screen should be inverted from top to bottom.

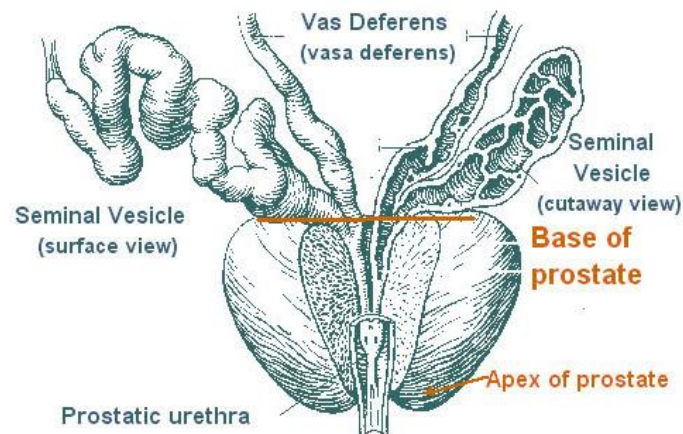
PATIENT POSITIONING: Patient should lay on their left side with right knee bent/up.

TRANSRECTAL IMAGES TO OBTAIN

STERILE OR BACTERIOSTATIC GEL PACKS AND SINGLE USE COVERS TO BE USED FOR ALL ENDOCAVITARY IMAGING.

PROSTATE

- Axial views of zones 1 through 6
- Axial views of the base, mid, and apex
- Axial cine sweep
- Axial measurement of width and AP dimensions.
- Color flow images of the base, mid, and apex of the prostate to show level of perfusion and areas of regional increased blood flow.
- Sagittal images of right, mid and left
- Sagittal cine sweep
- Sagittal measurement of length
- Assess any abnormality or abscess with and without color



<https://training.seer.cancer.gov/prostate/anatomy/>

SEMINAL VESICLES *obtain bilaterally*

- Axial views of the right and left seminal vesicles
- Measurement of length and AP dimensions of the right and left seminal vesicles
- Assess any abnormality or abscess with and without color

****Transrectal probe disinfection: See disinfection instructions using the Trophon Machine in the utility room.**

Additional Resources: <https://aium.s3.amazonaws.com/guidelines/prostate/ImageResources.pdf>

PROSTATE ULTRASOUND IMAGE LIST

TRANSRECTAL IMAGES	MODE
PROSTATE	
Axial Zones 1-6	2D
Axial Base	2D
Axial Mid	2D
Axial Apex	2D
Axial cine clip	Cine
Axial measurement of width and AP	2D +
Color flow of base, mid, apex	Color
Sagittal Right	2D
Sagittal Mid	2D
Sagittal Left	2D
Sagittal cine clip	Cine
Sagittal measurement of length	2D +
<i>Assess abnormality w and wo color</i>	<i>2D/Color</i>
SEMINAL VESICLES	
Seminal Vesicle Axial Right	2D
Seminal Vesicle Axial Left	2D
Measure length and AP	2D +

PROSTATE PROTOCOL HISTORY

	Date	Changes made	By whom
Created	11/22/2019		Manjiri Dighe S. Bornemeier
Format change	1/13/2023	Format change	Renee B Fitzgerald
Reviewed	2/29/24	Added: -Axial cine sweep -Sagittal images of right, mid and left -Sagittal cine sweep -Assess any abnormality or abscess with and without color	Protocol Meeting Attendees