

THYROID/NECK ULTRASOUND PROTOCOL (UTHYR or UHEADN)

PATIENT PREP: No prep.

TO BE USED FOR EVALUATION OF THE THYROID AND NECK AREA: Use the following protocol for ultrasound scans that include the area between the mandible and the clavicle and between the lateral margins of the right and left sternocleidomastoid muscles, including pre-surgical thyroidectomy planning and post thyroidectomy surveillance.

FOCUSED EXAMS OF PALPABLE AREAS – A focused exam may be performed on a palpable lump that does not involve the central cervical neck. (If the lump is located in the central neck, include a full thyroid exam.) Label images “Palpable area”

- Include a cine sweep of the neck on the side of concern assessing for other pathology or lymph adenopathy.
- Measure any pathology seen in 3 dimensions.
- Include color flow/MFI images of palpable area and any other pathology noted.
- If thyroid nodules are incidentally seen, perform a full thyroid exam.

PREFERRED SCANNING ORDER:

- Start with the right thyroid/neck and end with the left thyroid/neck.
- Start in a transverse plane, followed by a sagittal plane when beginning to scan the thyroid gland.
- Obtain all general thyroid images required before proceeding to imaging nodules when present.
- Document thyroid nodules and abnormal lymph nodes from superior to inferior on each side of the neck.

EQUIPMENT:

- Linear array transducer with frequency range of 10-18MHz or greater that allows for appropriate penetration and resolution depending on patient’s body habitus.

ULTRASOUND SETTINGS:

- Place the focus at the posterior margin of the thyroid gland or posterior to the inferior carotid artery. Extend the ultrasound depth to include several centimeters posterior to the thyroid gland. This will reduce the chance of missing a posterior lesion.

USE A VIEWPOINT DRAWING to illustrate any abnormal lymph nodes for the following patients (*see below for more specific instructions on how to create and attach illustration*)

- Pre-surgical thyroidectomy patients. The extension of lymph node involvement determines how radical the incision will be.
- Known thyroid cancer patients.
- Post thyroidectomy surveillance patients. Drawing is not needed if no abnormal nodes are seen.

IMAGES TO OBTAIN

THYROID GLAND:

ISTHMUS & MIDLINE

- Image showing both thyroid lobes. Use widescreen imaging as needed.
- Thyroid isthmus in transverse section with AP measurement.

RT & LT THYROID LOBES

TRANSVERSE

- Images in superior, mid, and inferior regions with corresponding labels.
- Two measurements in transverse at widest portion of lobe - height and width
- Transverse cine clip, superior to inferior.

SAGITTAL:

- Images in mid, lateral and medial regions with corresponding labels.
- Sagittal measurement of the maximum longitudinal dimension - length.
- Sagittal cine clip, medial to lateral.
- Color doppler image showing perfusion of gland.

THYROID NODULES:

IMAGES TO OBTAIN FOR NODULES: *(Include for the 2 most suspicious nodules on each side.)*

- Sagittal and transverse images without measurements
- Sagittal and transverse images with measurements using DUAL SCREEN and the technique described in measurement section below.
- Color flow image evaluating for peripheral or internal vascularity.
- MFI/MVI imaging to evaluate for presence of low flow when available.
- Document presence of calcifications - micro vs macro.
- ACR TIRADS to be reported for nodules to below specifications and evaluating the following characteristics: ***See additional info in REPORTING OF TIRADS SECTION***
 - Composition – Choose 1 characteristic from list
 - Echogenicity - Choose 1 characteristic from list
 - Shape - Choose 1 characteristic from list
 - Margin - If more than one type, choose the most suspicious
 - Echogenic Foci - Choose ALL that apply and add ALL points to score
 - Vascularity – peripheral vs internal flow

SUSPICIOUS NODULES: *Suspicious features are very hypoechoic nodules, irregular spiculated margins, calcifications/echogenic foci, extra thyroidal extension and taller than wide. If multiple nodules with suspicious features, then use the ordering below (if evaluating for the first time – please consult the radiologist for further clarification).*

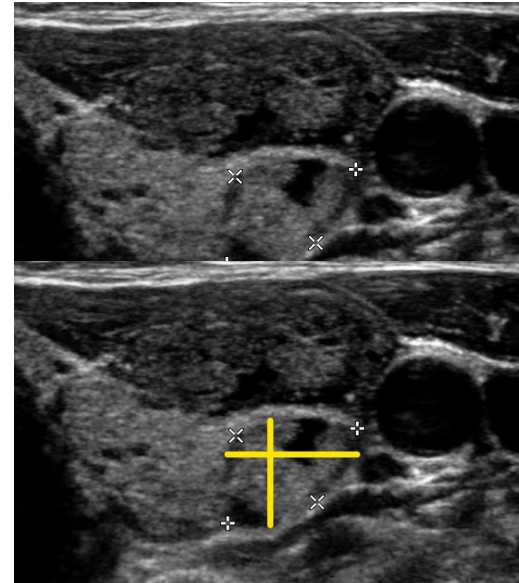
ORDER OF IMPORTANCE FOR MEASURING NODULES IN DESCENDING ORDER:

1. Very hypoechoic nodules
2. Nodules w echogenic foci or calcifications (without comet tail)
3. Nodules appearing taller-than-wide or with extra thyroidal extension.
4. Nodules >1cm, predominately solid
5. Nodules >1.5 cm, mixed solid or cystic

THYROID NODULES Continued...

MEASUREMENT TECHNIQUE OF THYROID NODULES:

- **USE DUAL SCREEN** to group measurements together.
- Always take an image with and without measurements.
- Nodules should be measured in three axes:
 - Two measurements in transverse:
 - (1) maximum dimension on an axial image
 - (2) maximum dimension perpendicular to the previous measurement on the same image
 - Third measurement in sagittal:
 - (3) maximum longitudinal dimension on a sagittal image
- For obliquely oriented nodules as in the example images, these measurements may be different than the ones determining whether it is taller-than-wide. A subjective assessment of this is sufficient unless it appears to be taller-than-wide. In these cases, a second measurement set would then be necessary. *See image.*
- Measurements should include the nodule's halo if one is present.



LABELING:

- When multiple nodules are present, number the nodules on each side starting superiorly with number 1. This makes it easier for subsequent, comparative scans.
- Once your report has been created, and you are certain of the nodules being reported, it is helpful to use post processing to label the images showing the dimensions with the corresponding nodule number.

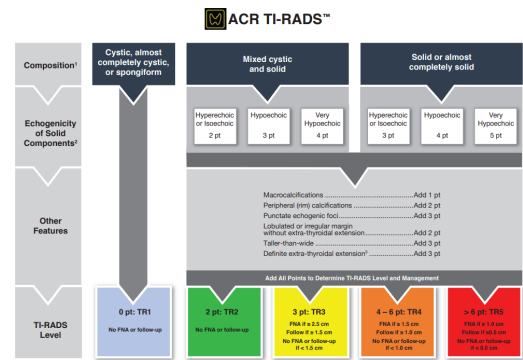
REPORTING:

- Measure and report the largest 2 nodules on each side.
- Prioritize the most suspicious looking and/or the largest if all appear similar. See order of importance in TIRADS section.
- If we have been following more than 2 nodules, continue to do so. The radiologist will determine when to stop reporting these and should be the one to eliminate them from the report.
- If a new nodule appears more concerning than those reported previously, add it to the report and the radiologist can decide if it should replace one of the others.
- In a multinodular goiter, include an estimate of the number of nodules in the report - "at least 6 nodules." Only measure the largest 2, or most suspicious, on each side.
- Sub-centimeter Nodules:
 - Nodules <1cm without concerning characteristics: Include a statement similar to the following: "Sub-centimeter nodule(s) without concerning characteristics are present."
 - Nodules suspicious in appearance <1cm: Include TIRADS for nodules that are under 1cm if they look suspicious for malignancy. Concerning features include - very hypoechoic, irregular margins, internal calcifications or taller-than-wide shape.
- PET positive nodules have approximately 40% chance of being malignant. Imaging should be reviewed with radiologist, preferably prior to the exam, in order to accurately locate the positive nodule and should always be reported with TIRADS regardless of size or appearance.

REPORTING OF TIRADS

Zoom to view or refer full size images available at end of protocol.

ACR TI-RADS				
COMPOSITION (Choose 1)	ECHOGENICITY (Choose 1)	SHAPE (Choose 1)	MARGIN (Choose 1)	ECHOGENIC FOCI (Choose all that apply)
Cystic or almost entirely cystic Spongiform Mixed cystic and solid Solid or almost completely solid	Anechoic Hypoechoic or isoechoic Hypoechoic Very hypoechoic	Majorly anechoic Majorly solid Majorly solid Majorly solid	Smooth Slightly irregular Irregular Discontinuous Ill-defined	None or large Pointed or diffuse Microcalcifications Peripheral rim Punctate Punctate Punctate Punctate
Add Points From All Categories to Determine TI-RADS Level				
0 Points TIR1 Benign No FNA	2 Points TIR2 Not Suspicious No FNA	3 Points TIR3 Minimally Suspicious FNA if > 2.5 cm Follow if > 1.5 cm	4 to 5 Points TIR4 Moderately Suspicious FNA if > 1.5 cm Follow if > 1 cm	7 Points or More TIR5 Highly Suspicious FNA if > 1 cm Follow if > 0.5 cm*
COMPOSITION (Choose 1) Spongiform: Composed predominantly of cysts or small cysts separated by thin septae. Do not add further points for other categories. Mixed cystic and solid: Assign points for predominant solid component. Assign 2 points if composition cannot be determined because of calcifications.	ECHOGENICITY (Choose 1) Anechoic: Applies to cystic or almost entirely cystic nodules. Hypoechoic/isoechoic/hypoechoic: Consider if adjacent parenchyma is very hypoechoic. Assign hypoechoic if adjacent parenchyma is not clearly visible. Assign 1 point if echogenicity cannot be determined.	SHAPE (Choose 1) Majorly anechoic: Should be assigned when the majority of the nodule is anechoic or hyperechoic. Do not add points for internal septae or septae. Majorly solid: This category is assigned to nodules that are predominantly solid. Assign 2 points if echogenicity cannot be determined.	MARGIN (Choose 1) Lobulated: Lobulation is the adjacent tissue irregular, jagged, spiculated, or sharp angles. Irregular: Irregular margins. Discontinuous: Discontinuous margins. Ill-defined: Ill-defined margins. Assign 2 points if margin cannot be determined.	ECHOGENIC FOCI (Choose all that apply) Large central anechoic: Largest of 2 or more central anechoic spaces. Microcalcifications: Coarse, punctate, peripheral rim, or punctate. Peripheral rim: Complete or incomplete. Punctate: Punctate or punctate. Punctate: Punctate or punctate. Punctate: Punctate or punctate. Assign 2 points if margin cannot be determined.



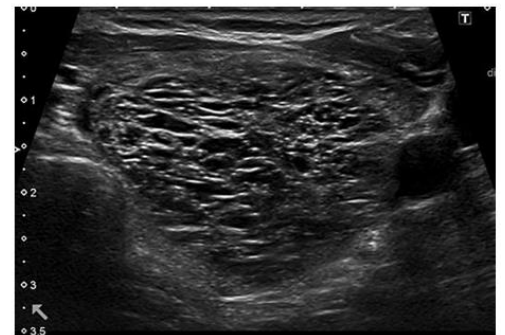
ASSUMPTIONS:

- If composition cannot be determined, choose “solid”.
- If echogenicity cannot be determined, choose “isoechoic”.
- For echogenicity, this feature refers to a nodule’s reflectivity relative to adjacent thyroid tissue, except for very hypoechoic nodules, in which the strap muscles are used as the basis for comparison.
- If the margin cannot be determined, choose “ill-defined margin”.
- **Spongiform nodules** should be assigned 0 points and are classified as TIRADS 1.
 - Do not add points for calcifications or other features. Small echogenic foci may be seen in spongiform nodules, where they probably represent the back walls of minute cysts. They are not suspicious in this circumstance and should not add to the point total of spongiform nodules.
 - Be certain when labeling a nodule :”spongiform” as it can dramatically change the TIRADS. The following is an example of a similar appearing SOLID NODULE with cystic spaces not >50% so does not warrant classification as spongiform. *See image.*
 - A spongiform nodule should be reported similarly to the following example:

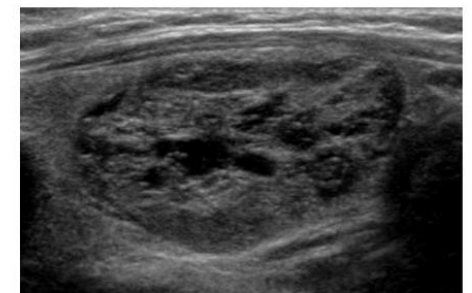
Nodule 3: 1.2 x 0.8 x 0.6 cm
 Location: superior pole
 Composition: spongiform = 0 points
 Score: 0

ACR-TIRADS score: TIRADS 1 (*Radiologist to enter TIRAD score*)

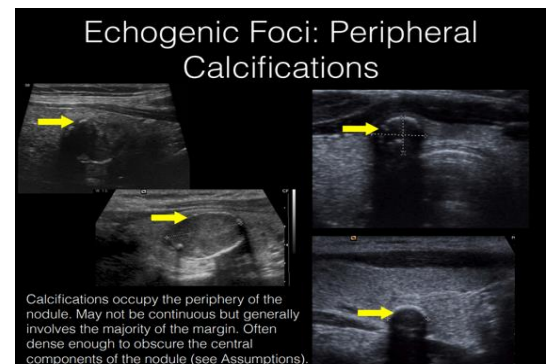
- **Echogenic Foci:** Choose **ALL** characteristics from list that apply and add **ALL points** to score.
 - For example, if there are macro and micro calcifications, you would add 4 points -1 point for macro and 3 points for micro.
- **Calcified rim:**
 - If rim calcifications obscure the nodule completely, choose composition to be “solid” and echogenicity to be “isoechoic”.
 - This is peripheral calcification (2 points) and should not be labeled as macro or micro calcification unless these are seen additional inside of the nodule.



Spongiform nodules have a sponge-like appearance, with at least 50% cystic composition and multiple microcystic spaces separated by thin septae or intervening isoechoic parenchyma.



Solid nodule with cystic spaces, not spongiform.



Calcifications occupy the periphery of the nodule. May not be continuous but generally involves the majority of the margin. Often dense enough to obscure the central components of the nodule (see Assumptions).

REFERENCE ACR TIRADS IMAGE ATLAS FOR MORE EXAMPLES & INFORMATION

<https://www.acr.org/-/media/ACR/Files/RADS/TI-RADS/ACR-TI-RADS-Atlas.pdf>

LYMPH NODE AND NECK DOCUMENTATION: To be done on all thyroid and neck ultrasound unless exam meets criteria for a focused ultrasound evaluation of palpable area. See criteria in introduction.

IMAGES TO OBTAIN OF NECK:

- **NECK CINE SWEEPS:** *Still images are not needed unless abnormal nodes are seen.*
- RT & LT CENTRAL CERVICAL NECK – (Levels 2/3/4 and a portion of 6.)
Superior to inferior, from the submandibular gland to clavicle.
- RT & LT POSTERIOR TRIANGLE - (Level 5)
Superior to inferior, focusing on area just behind the sternocleidomastoid muscle.

WHEN ABNORMAL LYMPH NODES ARE PRESENT: *(See rules below for pre-thyroidectomy patients.)*

IMAGES TO OBTAIN:

- 2D images without measurements in transverse and sagittal planes.
- 2D image with length and height measurements in a sagittal plane. Transverse measurement is not required.
- Use Color flow imaging of abnormal appearing lymph nodes.
- Use MFI color imaging if possible.

DEFINITIONS:

- Abnormal lymph node characteristics: Rounded, loss of fatty hilum, calcifications, cystic spaces, peripheral blood flow.
- Size: Consider >1cm in height enlarged, however since size is a less useful indicator, the other abnormal features override node size and smaller nodes should still be documented if abnormal in appearance. Submandibular lymph nodes have an upper limit of normal of 2cm in height.
- Rounded: A node should be assessed in the longitudinal plane comparing the length and the height of the node. If the height is greater than the length, it meets the criteria of being classified as rounded.

LABELING:

- Label any images of abnormal lymph nodes with the appropriate level of the neck.
- The A and B subsets do not need to be included for other levels, but it is helpful to do so for those in Level 5.
- Be descriptive enough that the lymph nodes reported can be found on follow up.

REPORTING:

- Only document abnormal lymph nodes.
- For lymph nodes over 1cm in size that otherwise appear normal, measure only the largest one. If multiple nodes are seen, state - "Multiple enlarged lymph nodes are seen in the R/L neck but otherwise are normal in appearance. Largest of these measures L x W x H cm."
- If you see an entire chain of abnormal nodes, state something similar to this, "Chain of 6 abnormal lymph nodes is seen extending from Level 2/submandibular gland to the clavicle. Largest of these measures L x H x W cm."
- If there are multiple abnormal nodes throughout multiple levels of the neck, include the statement, "Multiple abnormal lymph nodes are seen throughout the neck, The largest in each region of the neck are listed below." Report the following number of nodes: (This excludes pre-thyroidectomy patients):
 - The 2 most suspicious/largest in Level 2/3/4 combined.
 - The 1 most suspicious/largest in Level 1/6 combined.
 - The 1 most suspicious/largest in Level 5
- Use a VIEWPOINT drawing when applicable for pre and post thyroidectomy patients.

PARATHYROID ULTRASOUND: Include for ultrasounds with indications to rule out parathyroid disease or increased calcium levels. Always do a complete thyroid and neck exam. Please be aware that parathyroid lesions can be located in different areas in the neck, such as behind the trachea, and can be easily missed if not evaluated thoroughly.

TECHNIQUE:

- Patient's **neck should be turned** to the contralateral side to evaluate for the presence of parathyroid glands.
- Depth of image should be increased to visualize posterior to thyroid glands with the focus centered at the posterior thyroid.
- Dedicated parathyroid images should be taken and labeled "Parathyroid area" even if none are seen.

IMAGES TO OBTAIN:

- **CINE CLIPS OF RIGHT NECK: *Have the patient look to the left side.***
 - Transverse cine sweep from superior to inferior, from the submandibular gland to clavicle.
 - Sagittal cine sweep lateral to medial, from the carotid into the tracheal groove.
 - 2D images should be taken and labeled "Rt Parathyroid Area" even if none are seen.
- **CINE CLIPS OF LEFT NECK: *Have the patient look to the right side.***
 - Transverse cine sweep from superior to inferior, from submandibular gland to clavicle
 - Sagittal cine sweep lateral to medial, from the carotid into the tracheal groove.
 - 2D images should be taken and labeled "Left Parathyroid Area" even if none are seen.

WHEN PARATHYROID TISSUE IS VISUALIZED OR SUSPECTED:

- 2D images without and without measurements parathyroid tissue in transverse and sagittal planes.
- Color flow doppler and MFI/MVI of any suspected parathyroid tissue to evaluate for flow.

POSSIBLE LOCATION OF PARATHYROID GLANDS:

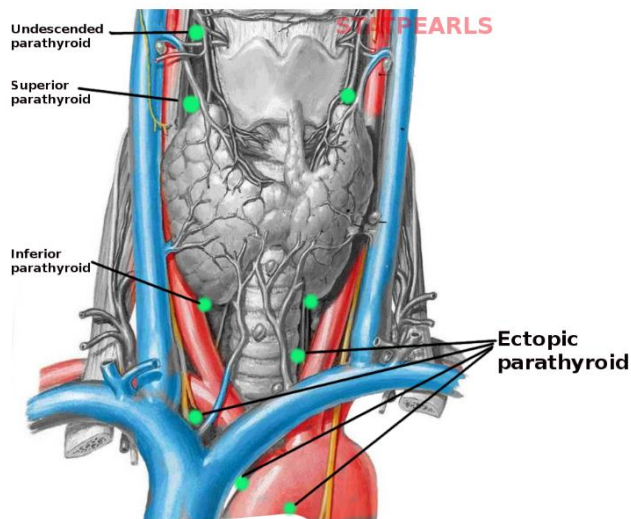
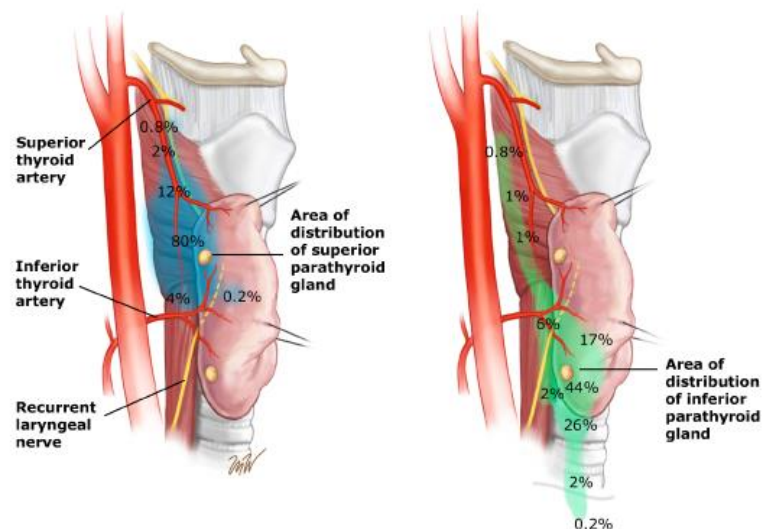


Image courtesy of S Bhimji



PRE-THYROIDECTOMY ULTRASOUND: In addition to a full thyroid ultrasound, a thorough evaluation of the neck for abnormal lymph nodes should be done. This information is very important for surgical planning and determining the extent of the incision needed.

TECHNIQUE:

- **ALL abnormal lymph nodes should be measured and included in the drawing, not just the largest ones.**
- Lymph nodes less than 1cm should also be reported if suspicious characteristics are seen, these lymph nodes need to be excised as well.
- Provide accurate and precise description of the location of any abnormal nodes.
- Always look for and describe the farthest lateral and farthest superior/inferior nodes seen. Location of these nodes will determine the extent of incision needed.

REPORTING:

- If multiple abnormal lymph nodes are visualized in a single chain, measure all of them and include all of them in the Viewpoint drawing. For reporting purposes, you can say something similar to this: "Chain of 6 abnormal lymph nodes is seen extending from Level 2/carotid bulb to the clavicle. Largest of these measures L x H x W cm."
- Use a **VIEWPOINT** drawing to illustrate any abnormal lymph nodes and attach the illustration to the exam. If no abnormal lymph nodes are found, this is not needed. See VIEWPOINT drawing directions below.

POST THYROIDECTOMY SURVEILLANCE ULTRASOUND: Thorough evaluation of the thyroid beds for residual tissue or recurrence should be done. It should include a full neck ultrasound looking for abnormal lymph nodes. It is important to see deep locations in the neck, especially posterior to the carotid where there is a high risk of recurrence.

CINE SWEEPS TO OBTAIN: *Still images are not needed unless abnormal nodes are seen.*

1. **RT & LT THYROID BED AND MEDIAL NECK** (Levels 1 and 6)
Superior to inferior, focusing on area medial to carotid, from just inferior to the hyoid bone to the clavicle.
2. **RT & LT CENTRAL CERVICAL NECK** – (Levels 2,3,4)
Superior to inferior, focusing on the area lateral to the carotid, from the submandibular gland to clavicle.
3. **RT & LT POSTERIOR TRIANGLE** - (Level 5)
Superior to inferior, focusing on area just behind the sternocleidomastoid muscle.

TECHNIQUE:

- If you see an entire chain of abnormal nodes, you could say something similar to this, "Chain of 6 abnormal lymph nodes is seen extending from Level 2/carotid bulb to the clavicle. Largest of these measures L x H x W cm."
- If there are multiple abnormal nodes throughout multiple levels of the neck, include the statement, "Multiple abnormal lymph nodes are seen throughout the neck, The largest in each region of the neck are listed below." Report the following number of nodes:
 - The 2 most suspicious/largest in Level 2/3/4 combined.
 - The 1 most suspicious/largest in Level 1/6 combined.
 - The 1 most suspicious/largest in Level 5
- Use a **VIEWPOINT** drawing to illustrate any abnormal lymph nodes and attach the illustration to the exam. If no abnormal lymph nodes are found, this is not needed. See VIEWPOINT drawing directions below.

VIEWPOINT DRAWING

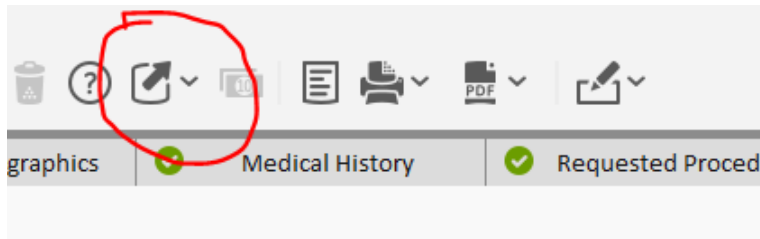
Use a Viewpoint drawing to illustrate any abnormal lymph nodes and attach the illustration to the Viewpoint exam for the following patients

- Pre-surgical thyroidectomy patients. The extension of lymph node involvement determines how radical the incision will be.
- Known thyroid cancer patients.
- Post thyroidectomy surveillance patients. It is not needed if only normal nodes are seen.

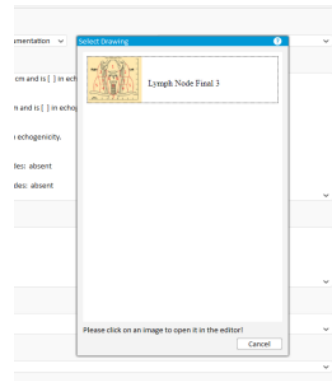
ATTACHING A VIEWPOINT DRAWING -

Used to illustrate any abnormal lymph nodes in pre and post thyroidectomy patients. Illustrate locations of nodes on neck level image and attach the illustration to the **VIEWPOINT** exam. If no abnormal lymph nodes are seen, this is not needed. Saving the illustration will attach it to the images in the VIEWPOINT study, and the illustration will be sent to GE PACS with the other images. To create a VIEWPOINT drawing -

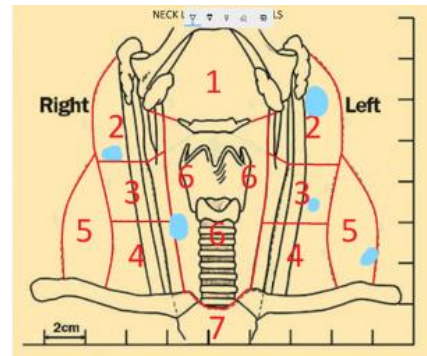
1- Within the Head and Neck VIEWPOINT templates, Select the Extensions icon, then Drawing Import.



2 - The Select Drawing pop up window will show the Neck illustration. Double click on this and the file will open as a Microsoft Paint file.



3 - Use the paint program to draw on the picture to map the location of abnormal lymph nodes. When you are done, save image using the disk icon at top of window and close the file. This will add drawing to the ultrasound images on Viewpoint.



the

NECK LYMPH NODES OF THE NECK:

Lymph nodes in the neck have been divided into **7 levels**, generally for the purpose of [squamous cell carcinoma](#) staging. This is however not all inclusive as several groups such as the supraclavicular, [parotid](#) and [retropharyngeal space](#) nodes are not accounted for in this system.

Level I

- below myohyoid muscle and above the lower margin of the hyoid bone
- anterior to the posterior border of the submandibular glands

Level II

- jugulodigastric
- base of skull to lower margin of hyoid bone
- anterior to the posterior border of sternocleidomastoid (SCM)
- posterior to the posterior border of the submandibular glands

Level III

- middle jugular nodes
- lower margin of hyoid to lower margin of cricoid cartilage
- anterior to the posterior border of SCM
- lateral to the medial margin of the CCA / ICA

Level IV

- low jugular nodes
- lower margin of cricoid cartilage to level of the clavicle
- anterior and medial to an oblique line drawn through the posterior edge of the sternocleidomastoid muscle and the posterolateral edge of the anterior scalene muscle⁴
- lateral to the medial margin of the CCA

Level V

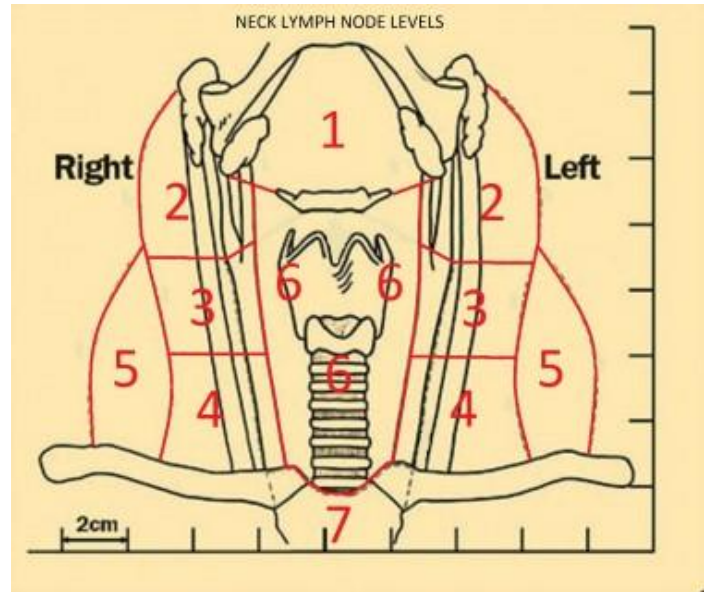
- posterior triangle nodes
 - **level Va** : superior half, posterior to levels II and III
 - **level Vb** : inferior half, posterior to level IV

Level VI

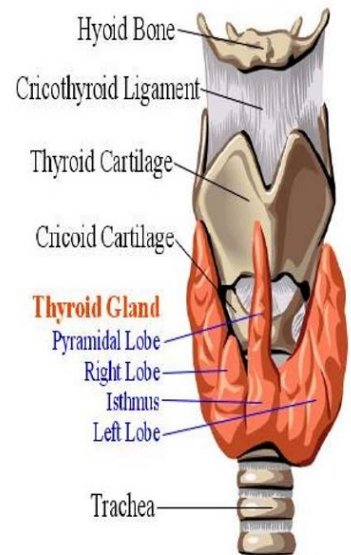
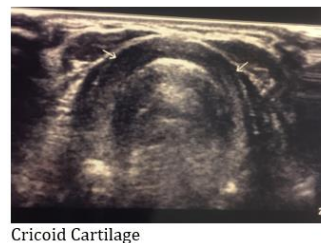
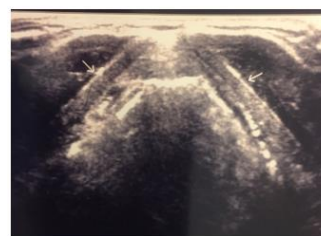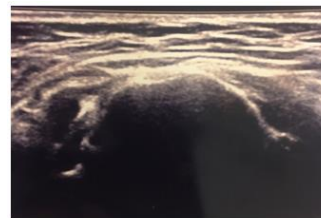- prelaryngeal / pretracheal / [Delphian node](#)
- from inferior margin of hyoid to manubrium
- in front of levels III and IV

Level VII

- superior mediastinal
- between CCAs, below top of manubrium



ULTRASOUND LANDMARKS



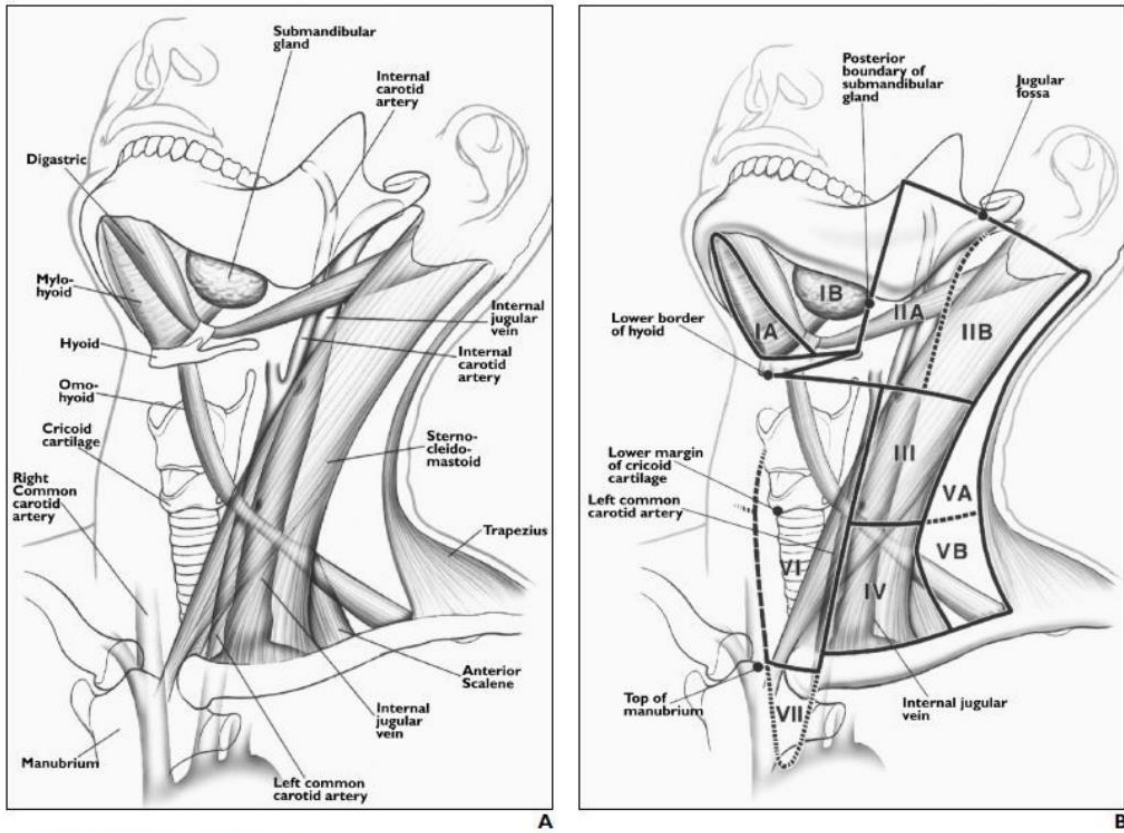
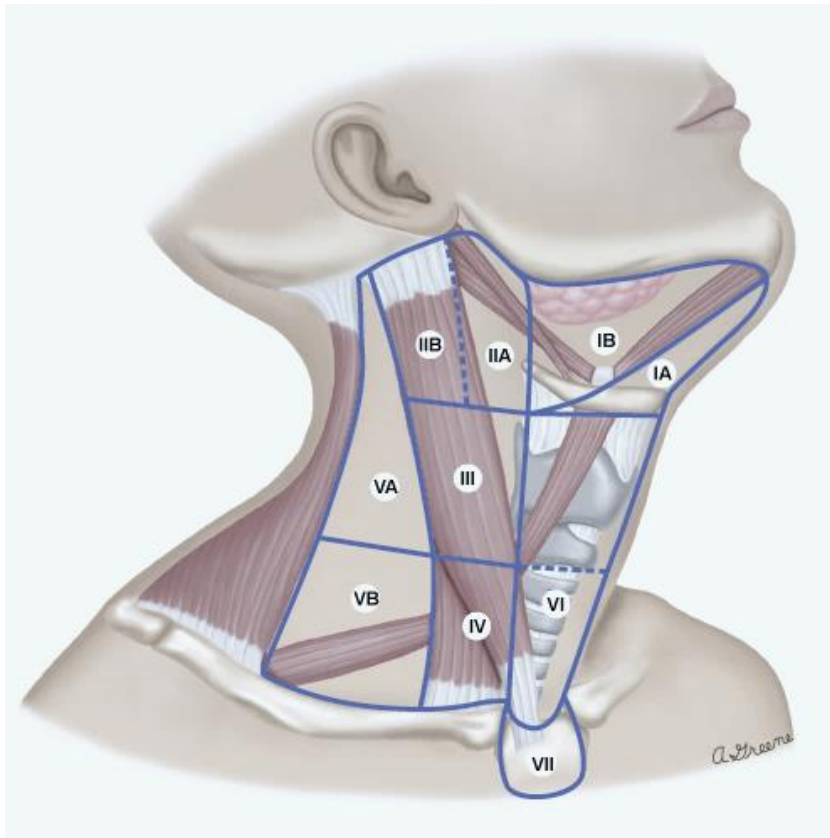
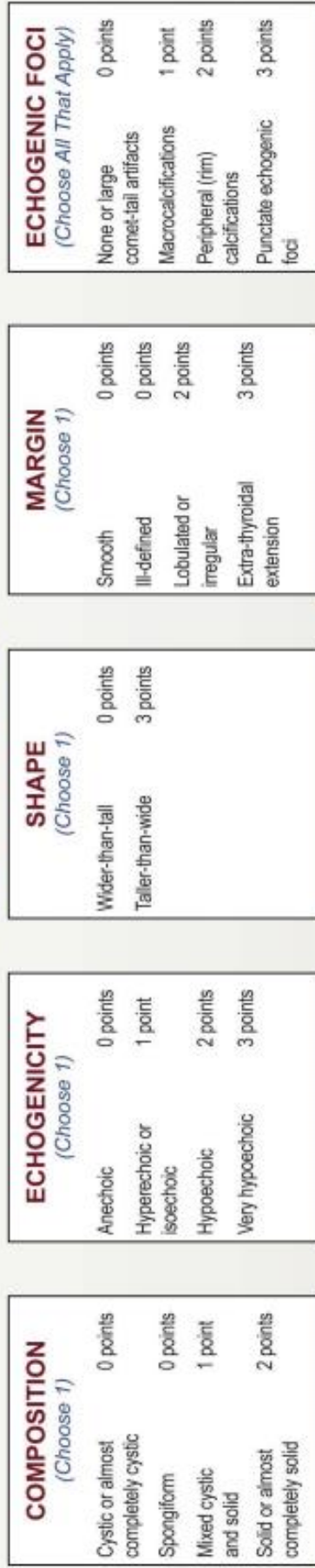

Fig. 1.—Neck as seen from left anterior view.
A, Drawing shows anatomy pertinent to nodal classification.
B, Drawing shows specific margins of anatomy seen in **A** that relate to definitions of classification levels. Note that line of separation between levels I and II is posterior margin of submandibular gland. Separation between levels II and III and level V is posterior edge of sternocleidomastoid muscle. Line of separation between levels IV and V is oblique line extending from posterior edge of sternocleidomastoid muscle to posterior edge of anterior scalene muscle. Posterior edge of internal jugular vein separates level IIA and IIB nodes. Carotid arteries separate levels III and IV from level VI. Top of manubrium separates levels VI and VII. (Reprinted with permission from [16])



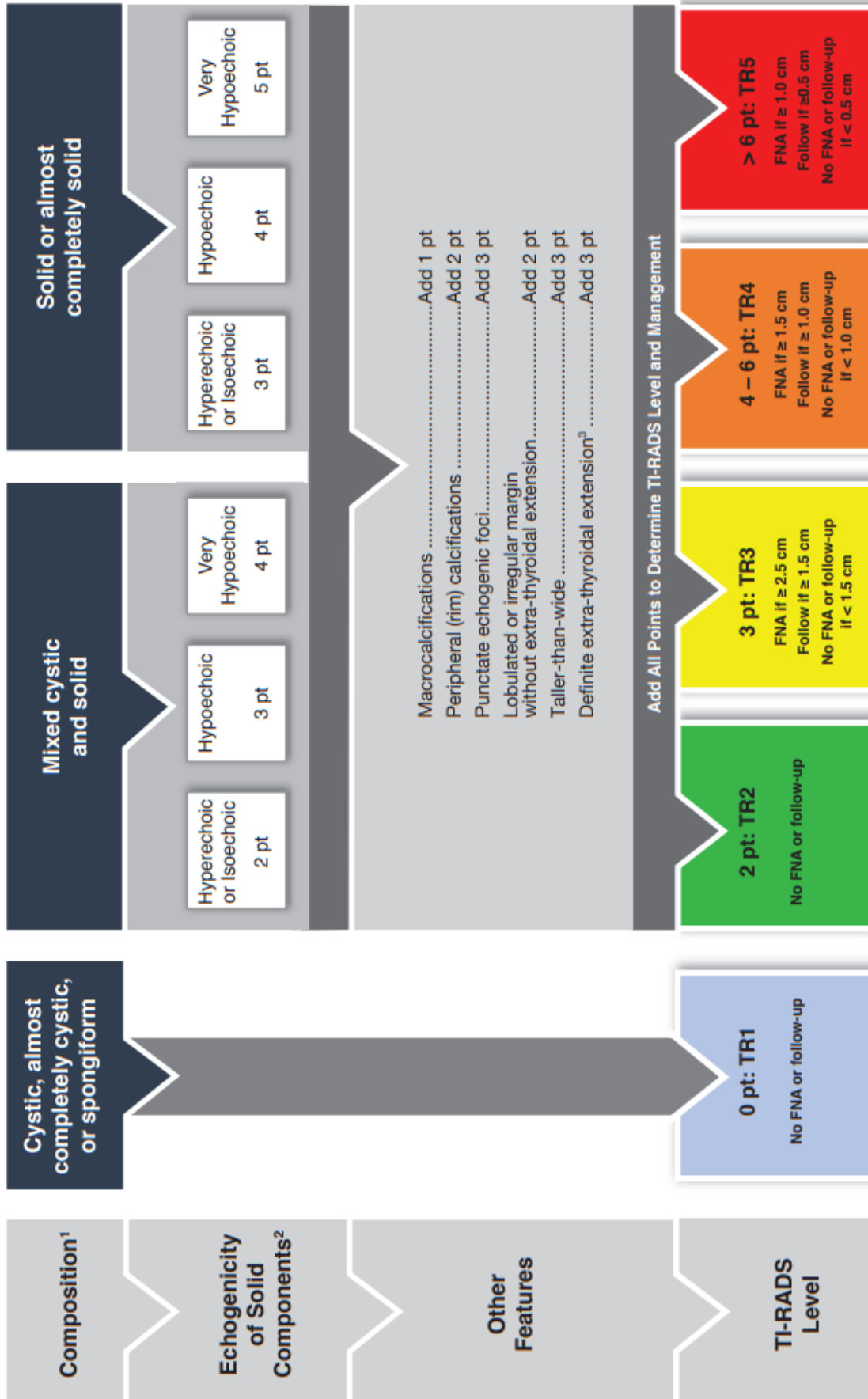
ACR TI-RADS



Add Points From All Categories to Determine TI-RADS Level

COMPOSITION	ECHOGENICITY	SHAPE	MARGIN	ECHOGENIC FOCI
<p>Spongiform: Composed predominantly (>50%) of small cystic spaces. Do not add further points for other categories.</p> <p>Mixed cystic and solid: Assign points for predominant solid component.</p> <p>Assign 2 points if composition cannot be determined because of calcification.</p>	<p>Anechoic: Applies to cystic or almost completely cystic nodules.</p> <p>Hyperchoic/isochoic/hypochoic: Compared to adjacent parenchyma.</p> <p>Very hypochoic: More hypochoic than strap muscles.</p> <p>Assign 1 point if echogenicity cannot be determined.</p>	<p>Taller-than-wide: Should be assessed on a transverse image with measurements parallel to sound beam for height and perpendicular to sound beam for width.</p> <p>This can usually be assessed by visual inspection.</p>	<p>Lobulated: Protrusions into adjacent tissue.</p> <p>Irregular: Jagged, spiculated, or sharp angles.</p> <p>Extra-thyroidal extension: Obvious invasion = malignancy.</p> <p>Assign 0 points if margin cannot be determined.</p>	<p>Large comet-tail artifacts: V-shaped, >1 mm, in cystic components.</p> <p>Macrocalcifications: Cause acoustic shadowing.</p> <p>Peripheral: Complete or incomplete along margin.</p> <p>Punctate echogenic foci: May have small comet-tail artifacts.</p>

*Refer to discussion of papillary microcarcinomas for 5-9 mm TR5 nodules.



¹ Classify nodule as solid if composition cannot be determined

² Classify nodule as isoechoic if echogenicity cannot be determined

³ Nodules with definite extra-thyroidal extension should be considered malignant until proven otherwise

THYROID ULTRASOUND IMAGE LIST

IMAGE	MODE	IMAGE	MODE
Thyroid Trans Mid (both lobes)	2D		
Thyroid Trans Mid (both lobes) w/color	Color		
Thyroid Isthmus Trans	2D +		
Thyroid Isthmus w/color	Color		
Thyroid Isthmus Long	2D +		
Right Thyroid Trans Sup	2D	Left Thyroid Trans Sup	2D
Right Thyroid Trans Mid	2D	Left Thyroid Trans Mid	2D
Right Thyroid Trans Mid w/ width and height	2D +	Left Thyroid Trans Mid w/ width & height	2D +
Right Thyroid Trans Inf	2D	Left Thyroid Trans Inf	2D
Right Thyroid Trans S-I cine	Cine	Left Thyroid Trans S-I cine	Cine
Right Thyroid Trans Mid w/color	Color	Left Thyroid Trans Mid w/color	Color
Right Thyroid Long Mid	2D	Left Thyroid Long Mid	2D
Right Thyroid Long Mid w/ length	2D +	Left Thyroid Long Mid w/ length	2D +
Right Thyroid Long Lat	2D	Left Thyroid Long Lat	2D
Right Thyroid Long Medial	2D	Left Thyroid Long Medial	2D
Right Thyroid Long M-L cine	Cine	Left Thyroid Long M-L cine	Cine
Right Thyroid Long Mid w/color	Color	Left Thyroid Long Mid w/color	Color
<i>Right Thy Nodule</i>	<i>Dual</i>	<i>Left Thy Nodule</i>	<i>Dual</i>
<i>Right Thy Nodule w measurements</i>	<i>Dual</i>	<i>Left Thy Nodule w measurements</i>	<i>Dual</i>
<i>Right Thy Nodule w/ color</i>	<i>Color</i>	<i>Left Thy Nodule w/ color</i>	<i>Color</i>
Right Neck Trans (Level 2-4) S-I cine	Cine	Left Neck Trans (Level 2-4) S-I cine	Cine
Right Neck Lateral (Level 5) S-I cine	Cine	Left Neck Trans Lateral (Level 5) S-I cine	Cine

POST THYROIDECTOMY IMAGE LIST

IMAGE	MODE
Right Neck Trans Levels 1/6	Cine
Right Neck Trans Levels 2/3/4	Cine
Right Neck Trans Level 5	Cine
Left Neck Trans Levels 1/6	Cine
Left Neck Trans Levels 2/3/4	Cine
Left Neck Trans Level 5	Cine

REFERENCES:

- AIUM PRACTICE PARAMETERS <https://onlinelibrary.wiley.com/doi/10.1002/jum.16251>
- Tessler, Middleton, Grant, et al. **ACR Thyroid Imaging, Reporting and Data System (TI-RADS): White Paper of the ACR TI-RADS Committee.** *Journal of the American College of Radiology Volume 14, Issue 5, May 2017*, 587-595 <https://doi.org/10.1016/j.jacr.2017.01.046>
- P. Som, H. Curtin, and A. Mancuso. **Imaging-Based Nodal Classification for Evaluation of Neck Metastatic Adenopathy.** *American Journal of Roentgenology Volume 174, Issue 3, March 2000* <https://doi.org/10.2214/ajr.174.3.1740837>
- ACR TIRADS Atlas <https://www.acr.org/-/media/ACR/Files/RADS/TI-RADS/ACR-TI-RADS-Atlas.pdf>
- <https://www.uptodate.com/contents/image/print?imageKey=ONC%2F54099> Adapted from: American Joint Committee on Cancer (AJCC), Chicago, Illinois. The original source for this material is the AJCC Cancer Staging Manual, Seventh Edition (2010) published by Springer New York, Inc.
- S Bhimji image from StatPearls Publishing; Treasure Island (FL): 2023 Jan. Embryology, Parathyroid.

THYROID HEAD AND NECK PROTOCOL HISTORY

	Date	Changes made	By whom
Updated	3/28/2018		Becky Marion
Reviewed	3/24/2022	ADDED Viewpoint drawing updates for new version of EPIC ADDED Color doppler image requirements ADDED Dual screen use for nodules	Protocol Meeting 3/24 Attendees
Added	4/12/2022	ADDED Pre thyroidectomy section ADDED Post thyroidectomy – measure most suspicious 3 on each side only” ADDED For >1cm and otherwise nrml nodes – list largest only	Renee Betit Fitzgerald
Changed	6/1/2023	CHANGE: Measure largest/most suspicious 2 nodules or lymph nodes. If we have been following more than 2, continue to do so.	Manjiri Dighe
Reviewed	6/21/2023	ADDED: Start in a transverse plane for thyroid images ADDED: Do all general thyroid images before nodules ADDED: Equipment section – linear array ADDED: Suspicious nodules section/order of importance. Reorganized into separate Measurement, Labeling and Reporting sections. ADDED: include nodule halo in measurement ADDED: MFI/MVI imaging to evaluate for presence of low flow when available. ADDED: Sub-centimeter Nodule statement ADDED: PET positive nodules statement to always include TIRADS regardless of size or appearance ADDED: More description on TIRADS classifications and link to Atlas ADDED: If there are multiple abnormal nodes throughout multiple levels of the neck ... include the statement, “Multiple abnormal lymph nodes are seen throughout the neck, The largest in each region of the neck are listed below.” Report the following number of nodes: -The 2 most suspicious/largest in Level 2/3/4 -The 1 most suspicious/largest in Level 1/6 -The 1 most suspicious/largest in Level 5 ADDED : Parathyroid location images REORGANIZED MEDIA ADDED Reference section	Protocol Meeting 6/21 Attendees: Manjiri Dighe Guilherme Cunha Shaun Bornemeier Dalene Edden Katie Toth Renee Betit Fitzgerald