

PORTAL VEIN THROMBOSIS ABDOMINAL DOPPLER ULTRASOUND PROTOCOL

BILLING CODE TO BE USED:

UABDL & UORGDL to be charged separately

PATIENT PREP: NPO at least 4 hours.

Exceptions can be made for urgent and ER exams. Include in the report that the patient was not NPO for exam when relevant.

****THIS STUDY INCLUDES AN ABDOMEN LIMITED EXAM AND LIMITED DOPPLER EXAM WITH COLOR AND SPECTRAL DOPPLER EVALUATION OF THE PORTAL VEINS, PORTAL CONFLUENCE, AND SPLENIC VEIN. IT WILL NOT INCLUDE HEPATIC ARTERIES OR HEPATIC VEINS****

****SEE SEPARATE PROTOCOLS FOR EVALUATION OF -**

- Full Abdominal Doppler
- Liver TIPS
- Pre-liver transplant workup
- Portal vein thrombosis

**For inpatients: If a recent abdominal ultrasound was done on the patient in the last 72 hours and an abdomen doppler is ordered, all images of the liver, biliary system, spleen and an assessment for collaterals and ascites should still be performed in addition to the liver dopplers requirements.

**If a patient is coming in for pain, document within the indication section what the current status of pain is. For instance, how long the patient has had pain, if it's getting worse or better, and where exactly the pain is. Always take an image where the patient is hurting the most, labeled as area of pain. When describing the pain, write "per patient, ..." in the indication. Example: Per the patient, his pain is now in the RUQ and getting worse.

**"Not well seen" to be stated if structure is not able to be completely evaluated. Include the reason why in relevant section of the report.

**Any masses, cysts, stones or abnormalities should be measured in three dimensions and have a 2D picture and a color image documented. MFI should be routinely used to evaluate perfusion and low flow structures as needed. Measure the 2 largest or most worrisome masses/cysts in any given structure and comment on the presence of additional if relevant.

**Cine clips to be added as needed for any abnormality seen.

****ALWAYS REVIEW PRIOR IMAGING WHEN AVAILABLE. IF A SPECIFIC SEGMENT OF THE PORTAL VEIN HAS SUSPECTED THROMBUS, INCLUDE A TARGETED EVALUATION OF THIS AREA WITH LABELS SHOWING CORRESPONDING LOCATION.**

IMAGES TO OBTAIN

PANCREAS *subcostal/epigastric approach*

Transverse images:

- Pancreas head, body, and tail.
- Pancreatic head showing porto-splenic confluence.
- Pancreatic body showing splenic vein
- Pancreatic body showing splenic vein with color
- Document and measure pancreatic duct if visible.

Sagittal images:

- Pancreatic head, body, and tail.

Take image of "Pancreas Area" if not well seen.

LEFT LIVER - *subcostal/epigastric approach*

Sagittal images:

- Left lobe with left portal vein and ligamentum teres.
- Left lobe with hepatic vein
- Cine clip sweeping through LHL in sagittal from medial to lateral

Transverse images:

- Left lobe visualizing dome of liver
- Left hepatic vein confluence into IVC with and without color
- Left lobe at left portal vein with and without color assessing for thrombus and direction of flow
- Cine clip sweeping through LHL in transverse from superior to inferior

CAUDATE LIVER - *subcostal/epigastric approach*

- Sagittal image of the caudate lobe.
- Transverse image of the caudate lobe.

RIGHT LIVER - *subcostal or intercostal approach*

Transverse images:

- Right lobe to visualize dome of liver
- Right and middle hepatic veins confluence into IVC with and without color
- Right lobe at right portal vein with and without color assessing for thrombus and direction of flow
- Right lobe and right kidney
- Cine clip sweeping through RHL in transverse from superior to inferior

Sagittal images:

- Right hemidiaphragm to assess for pleural effusions and ringdown.
- Right lobe and right portal vein
- Main interlobar fissure with gallbladder CHD and MPV
- Right lobe showing echotexture between liver and right kidney.
- Right lobe and right kidney documenting approximate liver size. Measurement of length of the liver is not needed unless requested.
- Cine clip sweeping through RHL in sagittal from medial to lateral

NOTE: If lateral edge or dome of liver is not seen in its entirety with patient in supine position, turn patient in LLD or raise head of bed and repeat RHL cine clips to visualize better.

MAIN PORTAL VEIN -

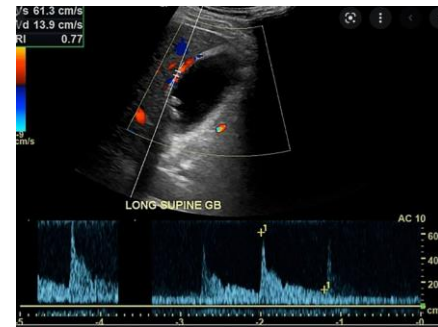- 2D image through MPV evaluating for thrombus
- Color image of MPV showing patency, filling and direction of flow

BILE DUCTS

- Sagittal image of CBD and CHD with measurements at the level of the porta hepatis. Color doppler should be used to distinguish ducts from vessels.
- If dilated, follow CBD as distal as possible to look for stones/mass and measure as distal as possible as well.
- Document and measure any intrahepatic bile duct dilatation with 2D and color imaging.

GALLBLADDER

- Sagittal image
- Transverse image
- Measurement of gallbladder wall in sagittal section only. Do not include liver surface. If liver edge is edematous, try to measure free GB wall. Normal wall thickness is <3mm.
- Take image and cine through GB if there is any abnormality (stones, polyp, adenomyomatosis.)
- Take color image of any mass seen.
- LLD POSITION: Transverse and sagittal image of gallbladder with patient in LLD position to check for stones/polyps and mobility.
- If evaluating for cholecystitis, or if suspicious GB findings such as thickened wall or distension:
 - Evaluate for Murphy's sign and include in the report.
 - Gallbladder length measurement. Normal <8cm
 - Color doppler of gallbladder wall to assess for hypervascularity
 - Spectral doppler velocity of the cystic artery which can be seen within wall of anterior gallbladder.
 - Normal velocity <40cm/s
 - If artery cannot be visualized, include color doppler of area and comment in report that it could not be seen.
 - Add code UORGDL if cystic artery is sampled.



RIGHT KIDNEY

- Sagittal image of right kidney in medial, middle, and lateral views.
- Sagittal measurement of right kidney.
- Transverse images of superior, mid, inferior right kidney.
- Demonstrate calculi, hydronephrosis or pelviectasis with a color image of the renal pelvis if present.
- **IF RENAL STONES ARE PRESENT:**
 - Measure renal stones in one largest dimension.
 - Demonstrate acoustic shadowing if possible.
 - Image with color to look for twinkle (can still be a stone if no twinkle shows).
- **IF HYDRONEPHROSIS, PELVIECTASIS, OR DILATED URETER PRESENT:**
 - Patient should void bladder and images should be taken to reassess degree of dilation with 2D and color images.

SPLEEN

- Sagittal and transverse images through spleen
- Sagittal length measurement of spleen
- Color Doppler image of any abnormality.

ASSESS FOR COLLATERALS

- Color image documenting any collaterals or varies if present in periportal area, LUQ, epigastric region, or the presence of a recanalized umbilical vein. If collaterals are seen, the splenic vein velocity and direction of flow should be documented.

LOWER QUADRANTS: Document RLQ and LLQ to check for ascites.

COLOR & SPECTRAL DOPPLER IMAGES TO OBTAIN

SWEEP SPEED should be set to SLOW (36cm/s) on the Philips machines and 2 or 3 on the GE machines.

You will be asked to repeat images if this is not the case. It is critical for comparison to priors to have the settings consistent.

PORTAL VEINS - LPV, RPV, MPV **VELOCITY with angle correction**

- Color images of MPV, Right PV and Left PV showing direction of flow, any filling defects and looking for thrombosis as far distal as possible.
- Direction of flow should be hepatopetal, towards the liver.
- The waveform should be continuous, monophasic flow.
- Some velocity variation from respiration is expected, measure where waveform is most consistent.
- Mild undulation or phasicity in the waveform is normal and can be seen especially if the patient is thin or has eaten a large meal recently.
- A pulsatile portal vein is defined as one that has >50% variation in velocities between the minimum and maximum velocity within the waveform. This can be seen with right heart failure, tricuspid regurge, HV and PV fistula, PHTN, malignant tumor invasion, and cirrhosis
- Normal diameter of MPV is 13-16mm
- Normal MPV velocity is >30-60 cm/s
- Normal RPV and LPV velocity is >10cm/s.
- Velocity should always be measured with angle correction.

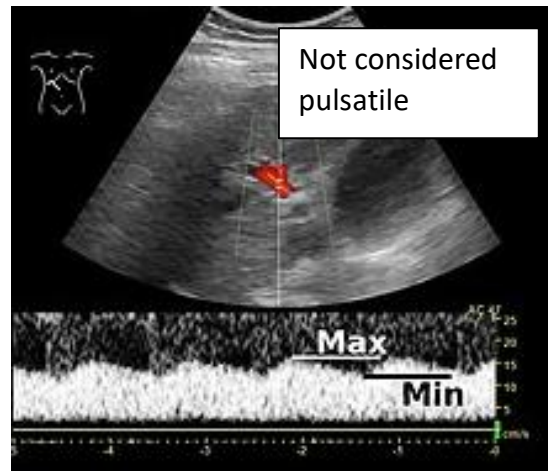
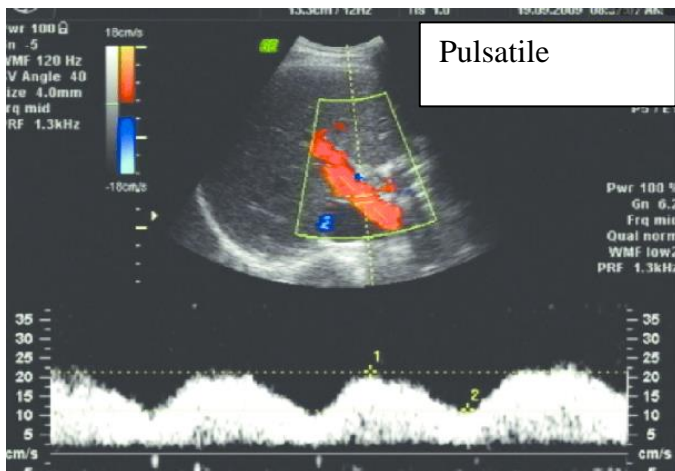
PORTAL VEIN CONFLUENCE

- Color and 2D images of the MPV down to the portal confluence.

SPLenic VEIN - **VELOCITY with angle correction**

- Color image of the splenic vein and SMV at the pancreas showing direction of flow.
- Splenic vein at splenic hilum - angle corrected velocity measurement. If patient has had a splenectomy no spectral is needed.

Portal veins are considered pulsatile if >50% variation in velocities or minimum and maximum velocity within the waveform.



****Additional Doppler information on image optimization and abnormal flow patterns can be found on the website in Guidelines and References.**

ABDOMINAL DOPPLER ULTRASOUND IMAGE LIST – PVT

IMAGE	MODE
Panc Trans H/B/T	2D
Panc Sag H/B/T	2D
Splenic Vein at panc	Color
<i>Panc Duct if dilated</i>	2D +
Left Liver Sag (at portal vein)	2D
Left Liver Sag (at hepatic vein)	2D
Left Liver Sag M-L	Cine
Caudate Liver Sag	2D
Caudate Liver Trans	2D
Left Liver Trans (at hepatic vein)	2D
Left Liver Trans (at portal vein)	2D
Left Liver Trans S-I	Cine
LPV <i>without color</i>	2D
LPV <i>w/ color</i>	Color
LPV <i>velocity w angle correction</i>	Spectral cm/s
Right Liver Trans (at dome)	2D
Right Liver Trans (at hepatic veins)	2D
Right Liver Trans (at portal vein)	2D
Right Liver Trans (at RK)	2D
Right Liver Trans S-I	Cine
Right Liver Sag/Rt Chest	2D
Right Liver Sag (at portal vein)	2D
Right Liver Sag (at main lobal fissure)	2D
Right Liver Sag / RK	2D
Right Liver Sag L-M	Cine
MPV <i>without color</i>	2D
MPV <i>w/ color</i>	Color
PV confluence <i>without color</i>	2D
PV confluence <i>w/ color</i>	Color
MPV <i>velocity w angle correction</i>	Spectral cm/s
RPV <i>without color</i>	2D
RPV <i>w/ color</i>	Color
RPV <i>velocity w angle correction</i>	Spectral cm/s

IMAGE	MODE
GB Sag	
GB Wall w/measurement	2D+
GB Sag w/ color	Color
GB Trans	2D
GB Sag LLD	2D
GB Trans LLD	2D
<i>GB length if r/o chole</i>	2D+
<i>Cystic duct if r/o chole</i>	Spectral
CHD w/measurement and color	Color+
CBD w/measurement and color	Color+
Right Kidney Sag Mid	2D
Right Kidney Sag Mid w/ measurement	2D +
Right Kidney Sag Med	2D
Right Kidney Sag Lat	2D
Right Kidney Trans Sup	2D
Right Kidney Trans Mid	2D
Right Kidney Trans Inf	2D
Spleen Sag x2	2D x2
Spleen Sag w/ measurement	2D +
Spleen Trans	2D
Splenic Vein	Spectral cm/s
RLQ	2D
LLQ	2D
Assess for collaterals	Color, 2D+
<i>For cirrhosis/HCC screening:</i>	<i>Linear</i>
<i>Capsule</i>	
<i>MFI for lesions</i>	<i>MFI</i>

PVT ABDOMINAL DOPPLER PROTOCOL HISTORY

	Date	Changes made	By whom
Created	03/03/22	Created separate protocol	Renee Betit Fitzgerald
Updated	10/25/21		Becky Marion
Updated	03/03/22	-Added color of SV at pancreas -Added Spectral of SV at hilum -Removed pelvis/bladder area images -Changed NPO requirement to 4 hrs	03/03/22 Protocol Meeting Attendees (Dighe, Lee, Kolokythas) (Document updated by Renee Betit Fitz)
Approved	03/14/2022		Manjiri Dighe
Added	10/27/2022	-Cine clips of RHL and LHL in Trv and Sag -Cystic artery and GB length if ruling out cholecystitis	Renee B Fitz
Added	4/15/2024	Images lists	Renee Betit Fitzgerald
Reviewed	6/27/2024	-Added assess for collaterals -Added: "For inpatients: If a recent abdominal ultrasound was done on the patient in the last 72 hours and an abdomen Doppler is ordered, a liver, spleen and doppler only study can be performed unless there are other areas are of interest in addition."	Protocol Meeting Attendees: Manjiri Dighe, Shaun Bornemeier, Dalene Edden, Renee Betit Fitzgerald, Becky Marion