

OBSTETRICAL ULTRASOUND BASIC AND DETAILED ANATOMY PROTOCOL

UOB2- Basic Anatomy to be used for patients that are not considered high risk.

UOBC -Detailed Anatomy to be performed for high-risk patients. (AMA, BMI >30, DM, known or previous fetal anomaly and all multiple gestations. See complete list of indication for Detailed Anatomy exams below.)

****Requisitions should be read carefully to ensure the proper exam is performed.**

**** See separate protocols for OB Follow Up, OB Limited exams and fetal anomalies.**

****Detailed Anatomy to be done on all multiple gestation pregnancies.**

****If any abnormal fetal findings are discovered on a Basic Anatomy Exam, the exam should be changed to a Detailed Anatomy Exam (UOBC) with corresponding images.**

**** See minimum additional images for FL or HL measuring <2%. If indicated, a referral will be made to MFM for further evaluation and full skeletal dysplasia survey**

**** See specialized protocol for TTTS (Twin to Twin Transfusion Syndrome) and TAPS (Twin Anemia Polycythemia Sequence) when requested with mono-di and mono-mono pregnancies.**

****If anatomy was cleared before 17 weeks 0 days, all anatomy images need to be repeated. If cleared on or after 17 weeks 0 days it does not need to be repeated.**

DATING: As a routine, use the date provided by the clinician or patient's known LMP. Working EDD in EPIC should be used if more than one date is provided. Use AIUM and ACOG dating criteria if dating is unknown.

IMAGES TO ACQUIRE

MATERNAL STRUCTURES:

UTERUS:

- Transverse images – Fundus, Mid and LUS
- Sagittal images – Right, Mid and Left
- If fibroids are present, measure the 3 largest/most significant. Fibroids located in the LUS should always be included due to potential delivery complications.

ADNEXA:

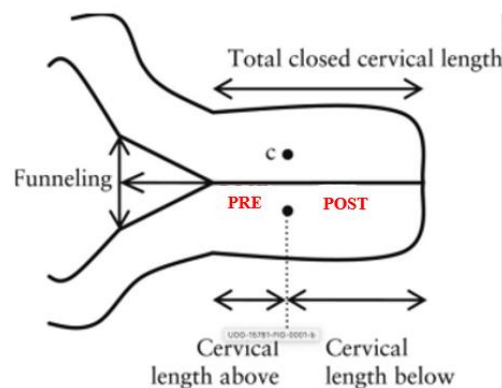
- Right and left adnexal regions

OVARIES:

- Sagittal image of right and left ovary with and without measurements
- Transverse image of right and left ovary with and without measurements

CERVICAL LENGTH AND STATUS:

- To be measured on all pregnancies less than 24 weeks gestational age. Normal cervical length is greater than 3.0 cm before 24 weeks.
- For pregnancies less than 24 weeks, if the cervix appears shortened, funneled, or if a cervical length is specifically the requested, a transvaginal (or translabial) ultrasound should be performed, and the following should be documented:
 - Total cervical length
 - Closed length of cervix
 - Open length if funneling is present (NOT funneling width). Greater than 50% open length of cervix is associated with higher risk of preterm delivery.
 - Document whether the cervix is dynamic. If dynamic, report shortest closed cervical length.
- Transvaginal ultrasound is not needed to evaluate the cervix after 24 weeks. If you find a short or dilated cervix transabdominally during an ultrasound exam, contact the referring provider and inform them of the findings. If the referring provider cannot be contacted, call triage nurse or L&D.
- For cerclage evaluation: Take 2D images, as well as cine sweeps, of the cervix showing suture in transverse and sagittal. Measure the total cervical length AND closed cervical length from stitch to external os. Do not apply fundal pressure or Valsalva with patients that have a cerclage.



PLACENTA:

1. Placental position in sagittal and transverse.
2. Relation to the internal os. If there appears to be a low-lying placenta, take measurements of distance from inferior margin of placenta (and from the sinus if present) to the internal os. A low-lying placenta is considered to be within 2 cm of the cervical os, or 1.1cm from the placental sinus.
3. Show thickness and echo texture and comment if abnormal.
4. Cord insertion into placenta showing location in transverse and sagittal (i.e., marginal, central, eccentric or velamentous).
5. If clinically indicated: placental masses, accessory or succenturiate lobes with location of connecting vascular supply to the primary placenta
6. Cine of any abnormality.
7. If accreta is suspected, see additional images needed at the end of protocol.

FETAL HEART RATE:

- Measure fetal heart rate M-Mode. Normal range is 110 – 170 bpm. If the fetal heart rate is above or below, refer to Urgent OB Contact List to contact charge nurse or L&D. If at outpatient clinics, contact the referring provider or on call OB staff for further instructions.

FETAL POSITION:

- Document fetal position.

FETAL SITUS:

- With a dual screen, image demonstrating fetal situs. In a transverse view, show side by side images of the fetal stomach and 4-Chamber heart on the left side of the fetus' body.
- If the fetus has changed position since presentation first documented, show new presentation of fetus to confirm which side is the left side of body.

AMNIOTIC FLUID VOLUME:

- Amniotic fluid volume evaluation before 24 weeks should be done subjectively.
- Calculate AFI after 24 weeks, or if appears abnormal before 24 weeks, using four quadrant measurements.
- For multiple gestations (twins, triplets, etc) measure the MVP. If Mono/mono gestation, use four quadrant measurements.
- Fluid pockets measured should be greater than 1cm in width.

AFI LEVELS (FOUR QUADRANTS)

| | |
|---------|-----------------|
| <5cm | Oligohydramnios |
| 5-8 cm | Borderline Low |
| 8-20cm | Normal |
| 20-24cm | Borderline High |
| >24cm | Polyhydramnios |

SINGLE MVP AMNIOTIC FLUID LEVELS

| | |
|-------|-----------------|
| <2cm | Oligohydramnios |
| 2-8cm | Normal |
| >8cm | Polyhydramnios |

FETAL BIOMETRY: Measure each of the following at least two times:

1. **BPD** –measured on an axial plane that traverses the thalami and cavum septum pellucidum.
2. **HC** – include in image with BPD.
3. **AC** - Transverse image through the upper abdomen at the level of the fetal stomach, umbilical vein and portal sinus.
4. **Humerus**
5. **Femur** - See additional image requirements at end of protocol if HL or FL measure <2% .

FETAL ANATOMY

FETAL HEAD AND NECK:

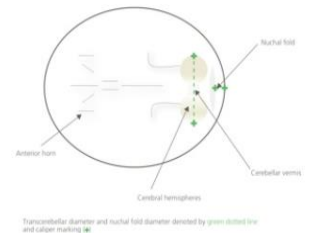
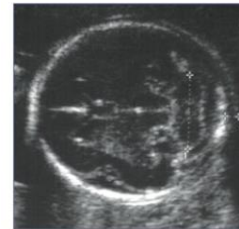Document the following:

1. Lateral ventricles with measurements (normal < 10mm)
2. Posterior Fossa/Cisterna Magna with measurements (normal < 10mm)
3. Cerebellum with transverse diameter
4. Cerebellar vermis
5. Falx
6. Cavum Septi Pellucidi (CSP)
7. Choroid Plexus
8. Nuchal fold - measurement at the level of cerebellum.

Normal is <6mm between 16-22 wks
Measure on separate image from PF measurement.

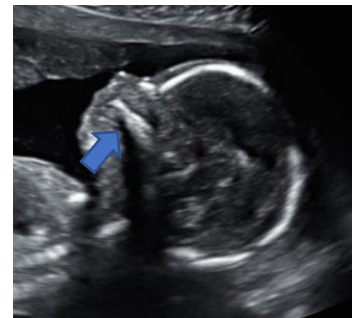If the nuchal looks thick after 22 weeks, then include a measurement.

9. Integrity and shape of the cranial vault/calvarium
10. Cine clip sweeping superior to inferior through the entire head showing structures of the brain.
11. ****If clinically indicated: Brain parenchyma, 3rd Ventricle, 4th Ventricle and Corpus Callosum****



FETAL FACE:

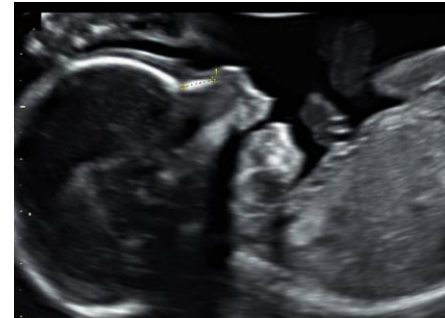- Fetal Profile with the nasal bone, chin and intact maxilla (blue arrow)
- Fetal nasal bone
- Fetal nose and lips in a coronal plane
- Fetal orbits and lens of eyes



FETAL FACE continued ...

FOR DETAILED ONLY:

- Fetal maxilla in transverse
- Fetal mandible in transverse
- Nasal bone measurement (normal >2.5mm)
- ****If clinically indicated: Palate, Tongue, Ear position and size, Inner/ Outer Orbital Diameter****



FETAL CHEST

- Lungs in transverse view, looking at symmetry and for presence of any mass or abnormality.

FETAL HEART:

These views will help evaluate the fetal heart to determine whether it is normal. While evaluating the fetal heart, attention should also be paid to the following characteristics to dramatically reduce the risk of missing any fetal heart abnormalities. Characteristics to evaluate while imaging the fetal heart are: POSITION, SIZE, FUNCTION, RHYTHM, PROPORTION, INTRAVENTRICULAR SEPTATION, AND ORIENTATION OF THE GREAT VESSELS.

HEART VIEWS REQUIRED:

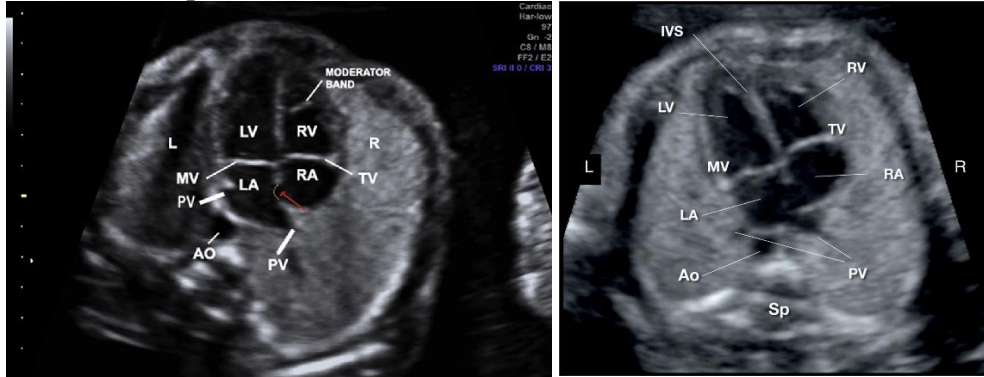
- 4-chamber view which includes view of entire chest.
- 4-chamber view that is zoomed in on the heart.
- 4-chamber view of heart showing the Intraventricular septum (IVS) perpendicular to the ultrasound beam.
- Lt ventricular outflow tract, 5-chamber view, which shows the relationship of the Aorta to the intraventricular septum.
- Right ventricular outflow tract, showing branching of the Pulmonary Artery.
- 3 Vessel View
- 3 Vessel Trachea
- 3 Vessel Trachea with color flow
- Cine clip in 4-chamber view showing contractility of heart.
- Cine clip of the 4-chamber view sweeping through the outflow tracks.
- Cine clip of the entire heart sweeping from base to apex, or vice versa.

For DETAILED ANATOMY only:

- Aortic Arch (color flow images can be used as a supplement if not well seen in 2D but is not required)
- Ductal Arch (color flow images can be used as a supplement if not well seen in 2D but is not required)
- IVC and SVC

HEART IMAGE EXAMPLES:

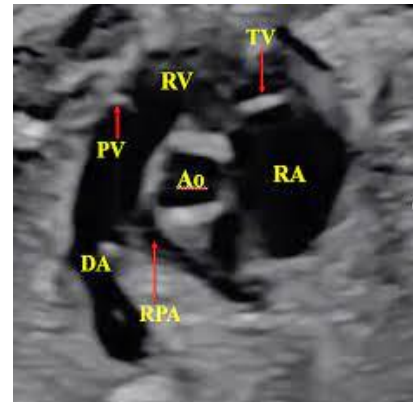
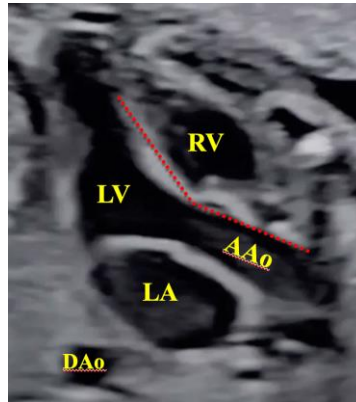
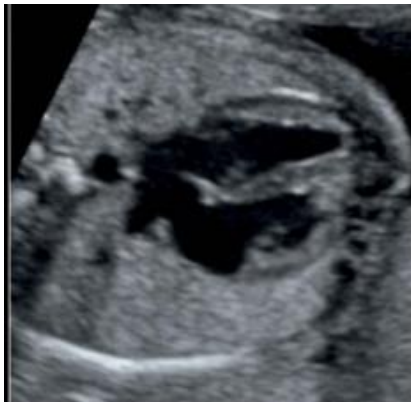4 Chamber Apical View:



4 CH / IVS

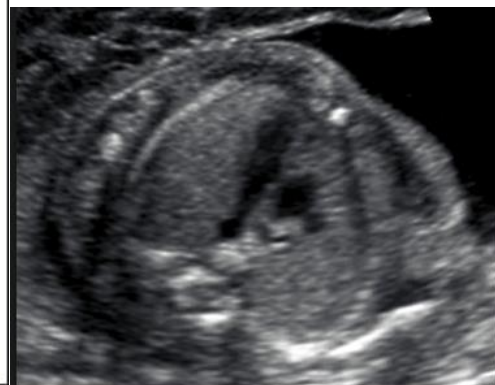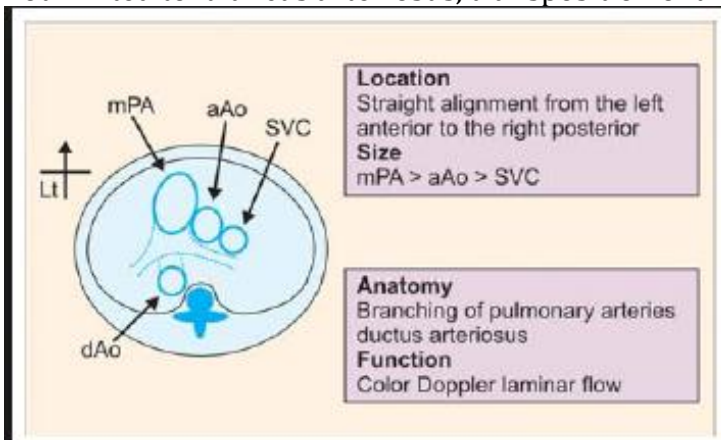
LVOT

RVOT

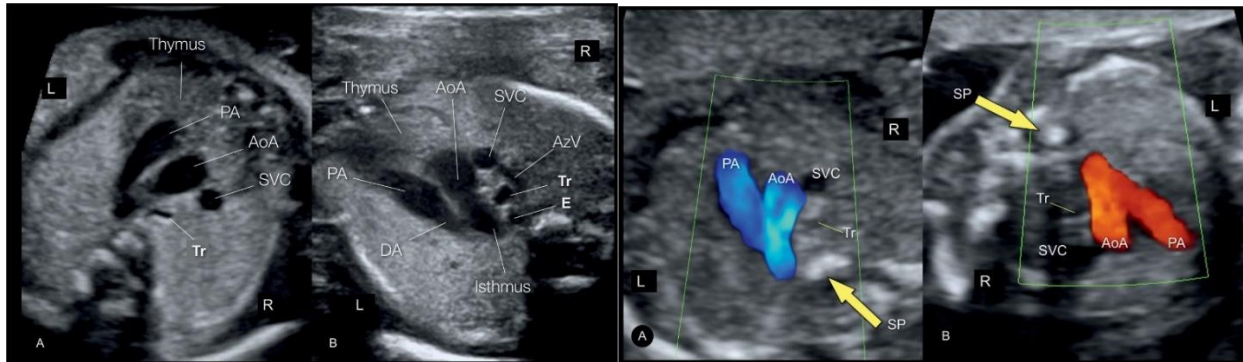


3 Vessel view (3VV):

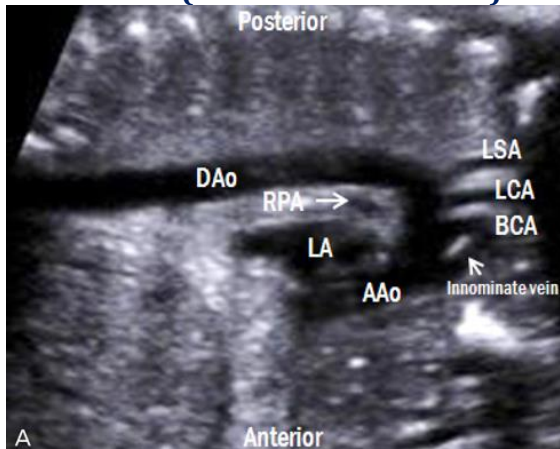
Helps diagnose conotruncal heart defects: Examples of conotruncal defects include, but are not limited to: truncus arteriosus, transposition of the great vessels, Tetralogy of Fallot.



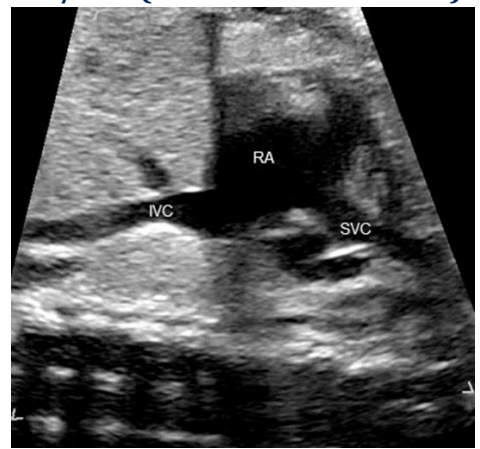
3VT / Three vessel Trachea view COLOR IMAGE to be included.



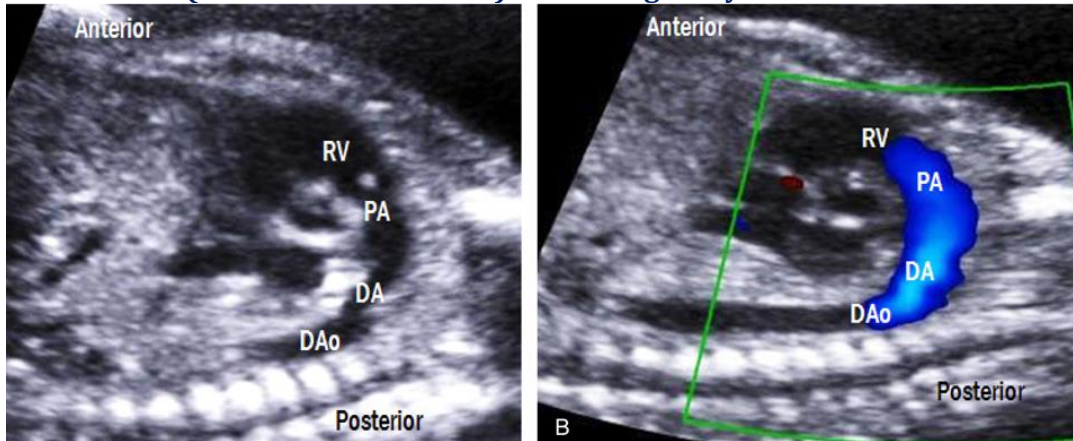
Aortic Arch (For DETAILED exam)



IVC/SVC (For DETAILED Exam)



Ductal Arch (For DETAILED exam) Color image only needed when not seen well in 2D.

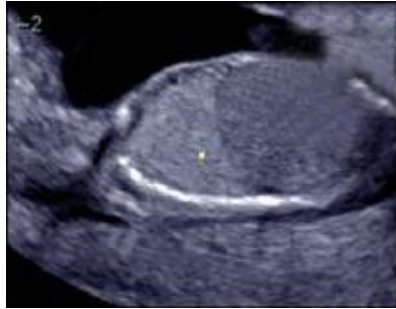


PERICARDIAL EFFUSION:

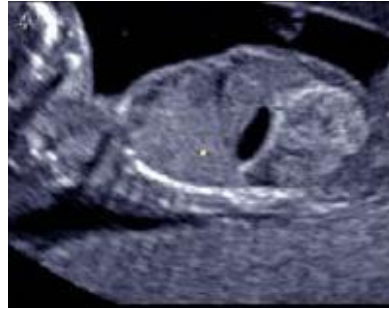- < 3 mm is considered normal in the 2nd and 3rd trimester. It may represent a hypoechoic myocardium or a small amount of pericardial fluid.
- Pericardial effusions may be seen with hydrops or other (primarily cardiac) structural anomalies.
- Recommendations—if the effusion is 3-7 mm evaluate for hydrops, arrhythmia, or structural anomalies. In the absence of these, the finding is likely clinically insignificant.

DIAPHRAGM:

- Sagittal views of the left and right sides of diaphragm.
- One cine clip through the diaphragm.



Right side



Left side

SPINE:

- 2D views of the cervical, thoracic, lumbar and sacral spine in longitudinal.
- 2D views of the cervical, thoracic, lumbar and sacral spine in transverse.
- Cine sweep in transverse

ABDOMEN:

- Measure Abdominal Circumference at least twice, to be included in the Biometry.
- Cord insertion and anterior abdominal wall showing the abdominal wall is intact on both sides of the cord insertion.
- **If clinically indicated: Liver, Small & Large Bowel, Adrenal Glands, Gallbladder and/or Spleen)**

KIDNEYS:

1. Longitudinal kidneys with measurements, labeled Left and Right.
2. Color, sagittal image of Aorta and both renal arteries.
3. Transverse picture of kidneys at the level of renal pelvis.
4. Look for ectopic kidneys if not able to see.
5. Measure any pelviectasis if present in a transverse view (APRPD anterior-posterior renal pelvic diameter) and follow the UTD Classification System.

Normal: 16-27weeks 6 days APRPD <4mm
>=28weeks APRPD <7mm

A1: 16-27weeks APRDP 4 to <7mm with central calyceal dilation
>=28weeks APRDP 7 to <10mm central calyceal dilation

A2-3: 16-27 weeks APRDP >=7mm
>=28weeks APRPD >=10mm

Exceptions:

- Peripheral calyceal dilation without meeting criteria is upgraded to A2-3
- Abnormal echogenic renal parenchyma is upgraded to A2-3
- Ureter dilation without meeting criteria is upgraded to A2-3

See Macro for Urinary Tract dilation.

BLADDER AND 3 VESSEL CORD:

- 2D transverse view of bladder.
- Document 3 vessel cord around bladder with Color Doppler.
- Include additional sagittal images of bladder if appears abnormal

EXTREMITIES:

- Measure the most anterior femur length at least twice, to be included in the Biometry
- Measure the most anterior humerus length at least twice, to be included in the Biometry. This only needs to be done once during anatomy scan at 16 weeks or greater.
- Document all long bones with proper labeling (Lt humerus, Rt R/U, etc.)—This only needs to be done once during anatomy scan at 16 weeks or greater.
- Bilateral hands – show fingers and thumb, include sweep if necessary to show all digits. Try to show at least one open hand, especially with other findings such as CPC's or increased risk of trisomy.
- Bilateral feet - show bottom of feet/footprint. Additional image and cine sweep showing the profile of foot with ankle to evaluate for club foot if it is suspected.
- See additional image requirements at end of protocol if HL or FL measure <2% .

GENITALIA:

- Documented in all pregnancies. Especially important in multiple gestational pregnancies and when medically indicated.
- If fetal sex is not wanted to be to known, select “Appears Normal” for the genitalia section of the report. **This field will be visible in My Chart.** If Cell Free DNA results are available, cross reference with ultrasound appearance.

****END OF BASIC AND DETAILED ANATOMY REQUIREMENTS****

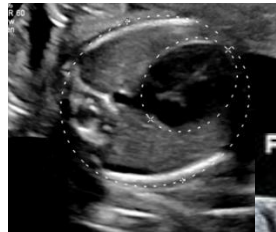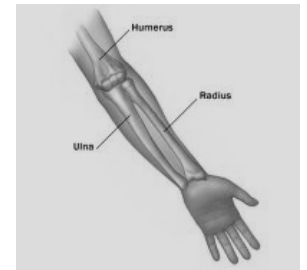
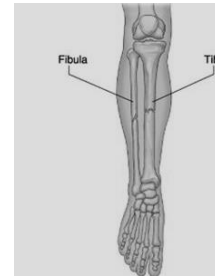
ADDITIONAL IMAGES TO BE OBTAINED AS NEEDED

LONG BONES (FL or HL) MEASURING <2%

1. MEASURE BILATERAL LONG BONES–

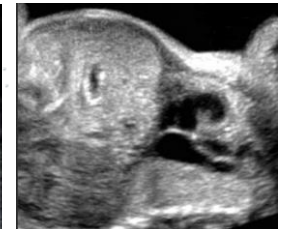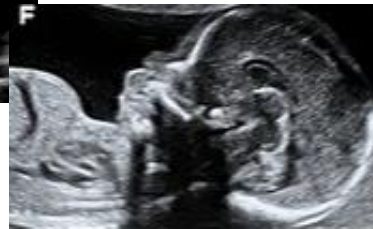Note whether long bones and skull show proper mineralization, curvatures, or fractures:

- **Femur**
- **Tibia**
- **Fibula**
- **Humerus**
- **Radius**
- **Ulna**



2. CHEST CIRCUMFERENCE

3. SAGITTAL AND CORONAL VIEWS OF CHEST showing chest size in relation to abdomen.



Bell shaped chest

4. DETAILED ANATOMY IMAGE REQUIREMENTS IF ONLY A BASIC WAS ORDERD

MULTIPLE GESTATIONS - Twins, Triplets, etc.

SEE SPECIALIZED PROTOCOL FOR TTTS (TWIN TO TWIN TRANSFUSION SYNDROME) AND TAPS (TWIN ANEMIA POLYCYTHEMIA SEQUENCE)

*****DETAILED ANATOMY SHOULD BE DONE FOR ALL MULTIPLE GESTATIONS**

Uterus: Sagittal and transverse cine sweeps to show orientation of fetuses.

Position: Document each fetus' position within in the uterus as well as presentation

- On each uterus image, label the location of fetuses with A, B etc.
- Include description of fetus location in Presentation section of Viewpoint report.

Membrane / Chronicity and Amnionity Assessment:

- Document the free-floating membrane between each fetus and ensure membrane is not adhered to fetus.
- Demonstrate membrane completely separating each fetus
- Document the thickness of membrane.
- Look for twin peak sign (diamniotic) or T-sign (monoamniotic)

Placenta:

- Document both placentas and determine if there are separate or shared placentas present. Show twin peak sign between placentas if visualized.
- Describe the location of each placenta

Amniotic Fluid:

- Amniotic fluid volume evaluation for multiples. Measure the deepest pocket (MVP) for each. In mono/mono pregnancies use 4 quadrants for AFI assessment.
- **TTTS** If Twin-twin-transfusion syndrome is suspected, at a minimum, document membrane, AFI on each, and each fetus' bladder. See TTTS Protocol for full image requirements.

FETAL HYDROPS ASSESSMENT: (Defined by two of the following)

1. Ascites
2. Integumentary edema
3. Pericardial effusion
4. Pleural effusion
5. Placentomegaly

SEE SEPARATE SPECIALIZED PROTOCOLS FOR:

- Multiple Gestation Complications – TTTS/TAPS
- Placenta Accreta Assessment
- Chest Anomalies:
 - Congenital Diaphragmatic Hernia (CDH)
 - CPAM (Congenital Pulmonary Airway Malformation)
 - Pulmonary Sequestration
- Gastroschisis/Omphalocele Anomalies
- Skeletal Dysplasia
- Fetal Arrhythmia

INDICATIONS FOR DETAILED ANATOMY SCAN

Indications for a detailed fetal anatomic examination include, but are not limited to the following conditions:

- Previous fetus or child with a congenital, genetic, or chromosomal abnormality
- Known or suspected fetal anomaly or known growth disorder in the current pregnancy
- Fetus at increased risk for a congenital anomaly, such as the following:
 - Maternal pregestational diabetes or gestational diabetes diagnosed before 24 weeks' gestation
 - Pregnancy conceived via assisted reproductive technology
 - High maternal body mass index (≥ 30 kg/m²)
 - Multiple gestations
 - Abnormal maternal serum analytes, including α -fetoprotein level and unconjugated estriol
 - Teratogen exposure
 - First-trimester nuchal translucency measurement of 3.0 mm or greater

- Fetus at increased risk for a genetic or chromosomal abnormality, such as the following:
 - Parental carrier of a chromosomal or genetic abnormality
 - Maternal age of 35 or older years at delivery
 - Positive screening test results for aneuploidy, including noninvasive prenatal testing
 - Soft aneuploidy marker noted on an ultrasound examination
 - First-trimester nuchal translucency of 3.0 mm or greater
- Other conditions affecting the fetus, including the following:
 - Congenital infections
 - Maternal drug dependence
 - Alloimmunization
 - Isoimmunization
 - Oligohydramnios
 - Polyhydramnios
- Suspected placenta PAC or risk factors for PAS such as placenta previa in the third trimester or a placenta overlying a prior cesarean scar site

OB DETAILED ANATOMY ULTRASOUND IMAGE LIST

| IMAGE | MODE |
|---|-------|
| GENERAL | |
| Presentation | 2D |
| FHR | Mmode |
| Situs | Dual |
| MATERNAL | |
| Uterus Sag Mid | 2D |
| Uterus Sag Right | 2D |
| Uterus Sag Left | 2D |
| Uterus Trans Sup | 2D |
| Uterus Trans Mid | 2D |
| Uterus Trans Inf | 2D |
| Rt Adnexa Trans | 2D |
| Rt Adnexa Sag | 2D |
| Rt Ovary Sag w/ & w/o measurements | 2D+ |
| Rt Ovary Trans w/ & w/o measurements | 2D+ |
| Lt Adnexa Trans | 2D |
| Lt Adnexa Sag | 2D |
| Lt Ovary Sag w/ a& w/o measurements | 2D+ |
| Lt Ovary Trans w/ & w/o measurements | 2D+ |
| Cervix | 2D+ |
| PLACENTA | |
| Placenta Edge / CVX Sag w/ meas if <2cm | 2D |
| Placenta Sag x2 | 2D |
| Placenta Trans x2 | 2D |
| Cord Origin Sag | 2D |
| Cord Origin Trans | 2D |
| HEAD | |
| BPD/HC x 3 | 2D+ |
| Lateral Ventricle w/ measurement | 2D+ |
| Choroid Plexus | 2D |
| Cavum Septum Pellucidum | 2D |
| Falx | 2D |
| Cerebellum w/ measurement | 2D+ |
| Cisterna Magna w/ measurement | 2D+ |
| Vermis | 2D |
| Head Cine S-I | Cne |
| Nuchal Fold w/ measurement | 2D+ |
| FACE | |
| Profile | 2D |
| Nasal Bone w/ measurement | 2D+ |
| Nose/Lips | 2D |
| Orbits | 2D |
| Maxilla | 2D |
| Mandible | 2D |
| CHEST | |
| Lungs | 2D |
| Rt Diaphragm | 2D |
| Lt Diaphragm | 2D |
| Diaphragm Cine R-L | Cine |

| IMAGE | MODE |
|---|------------|
| HEART | |
| 4CH | 2D |
| 4CH cine showing contractility | Cine |
| LVOT | 2D |
| RVOT | 2D |
| 3VV | 2D |
| 3VT | 2D |
| 3VT w/ color | Color |
| Intraventricular Septum | 2D |
| Heart Cine S-I | Cine |
| Ductal Arch | 2D |
| Aortic Arch | 2D |
| IVC/SVC | 2D |
| ABDOMEN | |
| AC x3 | 2D+ x3 |
| Stomach | 2D |
| Kidneys Trans | 2D |
| Rt Kidney Sag w/ measurement | 2D+ |
| Lt Kidney Sag w/ measurement | 2D+ |
| Renal arteries w/color | Color |
| Bladder | 2D |
| 3VC w/ color | Color |
| Cord insertion | 2D |
| Genitalia | 2D |
| SPINE | |
| Spine Sag | 2D |
| C Spine Trans | 2D |
| T Spine Trans | 2D |
| L Spine Trans | 2D |
| S Spine Trans | 2D |
| Spine Trans cine C-S | Cine |
| UPPER EXTREMITIES | |
| HL x3 | |
| Rt Humerus | Lt Humerus |
| Rt R/U | Lt R/U |
| Rt Hand | Lt Hand |
| Open Hand | |
| LOWER EXTREMITIES | |
| FL x 3 | |
| Rt Femur | Lt Fem |
| Rt T/F | Lt T/F |
| Rt Foot | Lt Foot |
| ADDITIONAL IMAGES IF NEEDED | |
| <i>ALL LONG BONES IF FL OR HL <2%, SKELETAL DYSPLASIA PROTOCOL IF FL or HL<1%</i> | |
| | |
| | |
| | |

OB BASIC ANATOMY ULTRASOUND IMAGE LIST

| IMAGE | MODE |
|--|-------|
| GENERAL | |
| Presentation | 2D |
| FHR | Mmode |
| Situs | Dual |
| MATERNAL | |
| Uterus Sag Mid | 2D |
| Uterus Sag Right | 2D |
| Uterus Sag Left | 2D |
| Uterus Trans Sup | 2D |
| Uterus Trans Mid | 2D |
| Uterus Trans Inf | 2D |
| Rt Adnexa Trans | 2D |
| Rt Adnexa Sag | 2D |
| Rt Ovary Sag w/ & w/o measurement | 2D+ |
| Rt Ovary Trans w/ & w/o measurements | 2D+ |
| Lt Adnexa Trans | 2D |
| Lt Adnexa Sag | 2D |
| Lt Ovary Sag w/ & w/o measurements | 2D+ |
| Lt Ovary Trans w/ & w/o measurements | 2D+ |
| Cervix | 2D+ |
| PLACENTA | |
| Placenta Edge / CVX Sag w/ measurement if <2cm | 2D |
| Placenta Sag x2 | 2D |
| Placenta Trans x2 | 2D |
| Cord Origin Sag | 2D |
| Cord Origin Trans | 2D |
| HEAD | |
| BPD/HC x 3 | 2D+ |
| Lateral Ventricle w/ measurement | 2D+ |
| Choroid Plexus | 2D |
| Cavum Septum Pellucidum | 2D |
| Cerebellum w/ measurement | 2D+ |
| Cisterna Magna w/ measurement | 2D+ |
| Head Cine S-I | Cine |
| Nuchal Fold w/ measurement | 2D+ |
| FACE | |
| Profile | 2D |
| Nose/Lips | 2D |
| Orbits | 2D |
| CHEST | |
| Rt Diaphragm | 2D |
| Lt Diaphragm | 2D |
| Diaphragm Cine R-L | Cine |
| | |
| | |
| | |
| | |

| IMAGE | MODE | |
|--|------------|-----|
| HEART | | |
| 4CH | 2D | |
| 4CH cine showing contractility | Cine | |
| LVOT | 2D | |
| RVOT | 2D | |
| 3VV | 2D | |
| 3VT | 2D | |
| 3VT w/ color | Color | |
| Intraventricular Septum | 2D | |
| Heart Cine S-I | Cine | |
| ABDOMEN | | |
| AC x3 | 2D+ | |
| Stomach | 2D | |
| Kidneys Trans | 2D | |
| Rt Kidney Sag w/ measurement | 2D+ | |
| Lt Kidney Sag w/ measurement | 2D+ | |
| Renal arteries w/color | Color | |
| Bladder | 2D | |
| 3VC w/ color | Color | |
| Cord insertion | 2D | |
| Genitalia | 2D | |
| SPINE | | |
| Spine Sag | 2D | |
| C Spine Trans | 2D | |
| T Spine Trans | 2D | |
| L Spine Trans | 2D | |
| S Spine Trans | 2D | |
| Spine Trans cine C-S | Cine | |
| UPPER EXTREMITIES | | |
| HL x3 | 2D+ | |
| Rt Humerus | Lt Humerus | 2D |
| Rt R/U | Lt R/U | 2D |
| Rt Hand | Lt Hand | 2D |
| +Open Hand | | |
| LOWER EXTREMITIES | | |
| FL x 3 | | 2D+ |
| Rt Femur | Lt Fem | 2D |
| Rt T/F | Lt T/F | 2D |
| Rt Foot | Lt Foot | 2D |
| ADDITIONAL IMAGES IF NEEDED | | |
| <i>ALL LONG BONES IF FL OR HL <2%,</i> | | |
| <i>SKELETAL DYSPLASIA PROTOCOL IF FL or HL<1%</i> | | |
| <i>ADD DETAILED VIEWS IF ANY ABNORMALITY SEEN</i> | | |
| <i>Falx Vermis</i> | | |
| <i>Nasal Bone w/ measurement</i> | | |
| <i>Maxilla Mandible</i> | | |
| <i>Lungs</i> | | |
| <i>Ductal Arch Aortic Arch IVC/SVC</i> | | |

OB BASIC AND DETAILED ANATOMY PROTOCOL HISTORY

| | Date | Changes made | By whom |
|----------|------------|---|---|
| Updated | 3/12/2021 | | Becky Marion |
| Updated | | Color of 3VT added | Renee Betit Fitz |
| Updated | 5/1/2022 | <p>Format Changed and General info added</p> <p>Took out :</p> <ul style="list-style-type: none"> -Valsalva/Fundal Pressure for cervix eval, -3VC in fluid -Sagittal images of Maxilla and mandible - sagittal images of bladder unless indicated <p>Added :</p> <ul style="list-style-type: none"> -Cine Sweeps of cerclage & measurement info -Dual Screen for situs and additional presentation image if position changed -4ch heart cine sweep to show contractility -Image of IVS showing septum -Updated heart image examples -Clarified hand and feet image requirements -Genitalia section updated. -Multiples section updated to reflect images we take -UA/MCA sections added from "Doppler statement" -Hydrops section added -Precrreta section details added -Anomalies made into separate protocols -Indications for Detailed added | <p>4/28/2022 Protocol Review Meeting. Attending physicians present Dighe, Cheng, Ma</p> <p>Updates done by Renee Betit Fitzgerald</p> |
| Approved | 5/5/2022 | | Manjiri Dighe |
| Added | 10/25/2022 | Placenta Accreta Protocol List 1-10 Cine clip from base to apex of heart Cine clip of head/brain sup to inf | Renee B Fitz |
| Changed | 12/12/22 | If anatomy was cleared before 17 weeks 0 days, all anatomy images need to be repeated except extremities. | Renee B Fitz |
| Added | 1/31/2023 | Added to align w AIUM standards: Basic – 3VT views Detailed – Falx, vermis, lungs, NB with meas | |
| Added | 1/31/2023 | Added agreed on AFI chart | Manjiri Dighe Edith Cheng Renee Betit Fitz |
| Changed | 5/5/2023 | Cerclage image was incorrect. Pre and Post labels revised. Removed Placenta Accreta section – see specialized protocol | OB Protocol meeting 4/27/23 Dighe, Cheng, Ma, Hitti, Shaun, Renee, Dalene |
| Added | 5/23/2023 | If anatomy cleared on or after 17w0d it does not need to be repeated. | Manjiri Dighe |
| Copied | | Skeletal dysplasia protocol parameters added to intro | |
| Changed | 10/28/2023 | New nuchal thickness criteria 16-22wks <6mm Measure NF until 22wks and after if appears thickened Nasal bone - normal >2.5mm | OB Protocol meeting 6/27/23 Dighe, Cheng, Ma, Shaun, Renee, Dalene, Becky |

OB BASIC AND DETAILED ANATOMY PROTOCOL HISTORY cont...

| | Date | Changes made | By whom |
|--------|-----------|---|---|
| Change | 7/25/2024 | <p>Added 1.1cm for cut off of low lying from placental sinus</p> <p>Workflow change: Due to time restraints, patients will be referred to MFM for full survey and workup if long bones are incidentally seen on routine imaging.</p> <p>Minimum images to still obtain are: Bilateral long bones, chest circumference, sagittal image of chest. Detailed anatomy views if a basic was ordered</p> | <p>Combined Protocol Meeting MFM/RAD Attendees:</p> <p>M. Dighe, E. Cheng, J. Hitti, M. Richley, S Bornemeier, B. Marion, R. Betit Fitzgerald</p> |
| | | | |
| | | | |
| | | | |
| | | | |
| | | | |
| | | | |
| | | | |
| | | | |
| | | | |
| | | | |
| | | | |
| | | | |
| | | | |
| | | | |
| | | | |
| | | | |