

# FIRST TRIMESTER DETAILED ANATOMY

## CHALLENGE #2

Hopefully, you have been able to practice getting the images from the first challenge of the fetal brain (see email from 10/4). We are going to continue to build on brain anatomy for Challenge #2. We are used to seeing this anatomy in second trimester anatomy cases, so these shouldn't be too hard. We just need to be sure to make the effort to look closer when they are a little smaller!

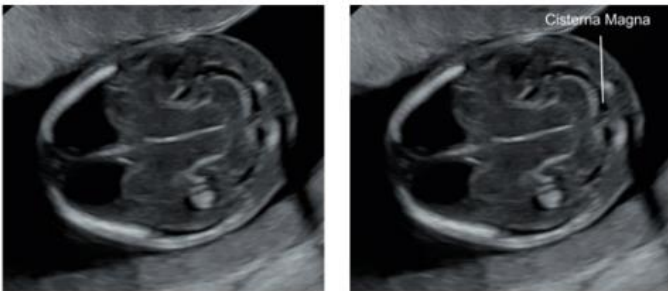
Please use the next 2 weeks to continue to get the sagittal and coronal brain images from **Challenge #1 PLUS add the 3 new additional images** below on any first trimester cases scanned. Again, don't spend too much extra time acquiring these, especially if the patient does not scan well.

To be sure that everyone is practicing these views, please mark in the QA field of Viewpoint that you have done it by selecting the "1<sup>st</sup> Tri Challenge" box from the cases you attempt these on. Everyone should have done at least one case that shows both images Challenge 1 & 2 by the end of the month, 10/31. If for some reason you are not able to do this, it is your job to let me know why so that I know you were not just neglecting to do it or not reading your emails.

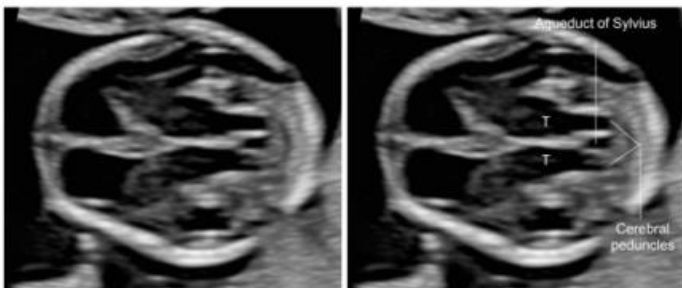
To keep track of our progress as we move through these challenges, you can always go to the "What's New" tab of the website to find the individual challenges, as well as a summary of what we are working on. I will keep it up to date.  
<https://depts.washington.edu/usrad/whats-new/>

Thanks everyone! We are going to be amazing at these cases by time we need to do them, I just know it!  
Renee

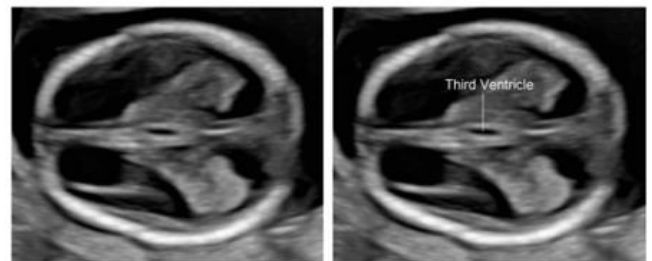
### Posterior fossa



### Transthalamic plane – thalami, cerebral peduncles, third ventricle and aqueduct of Sylvius



### Third ventricle



10/19/2023