

LIVER TIPS ABDOMINAL DOPPLER ULTRASOUND PROTOCOL

BILLING CODE TO BE USED:

UABDD - This is a combined charge of UABDL and UORGDC

UABDC & UORGDC to be charged separately if you are doing a Complete Abdomen Exam

PATIENT PREP: NPO at least 4 hours.

Exceptions can be made for urgent and ER exams.

Include in the report that the patient was not NPO for exam when relevant.

****THIS STUDY INCLUDES AN ABDOMEN LIMITED EXAM WITH COMPLETE DOPPLER EXAM EVALUATING COLOR AND SPECTRAL DOPPLER OF TIPS, PORTAL VEINS, HEPATIC ARTERIES, HEPATIC VEINS, IVC AND SPLENIC VEIN.**

****IF AN HCC SCREENING IS ORDERED ON A PATIENT WITH A TIPS, AND DOPPLERS ARE NOT REQUESTED, PERFORM ONLY A HCC SCREENING PROTOCOL WITHOUT DOPPLERS.**

**SEE SEPARATE PROTOCOLS FOR EVALUATION OF -

- General Abdominal Doppler
- Pre-liver transplant workup
- Portal vein thrombosis
- Portal hypertension

**ALWAYS INCLUDE THE FOLLOWING INFORMATION IN THE PATIENT HISTORY SECTION OF THE REPORT-

- Placement or revision date
- Baseline velocities
- TIPS location (Most commonly placed from MPV or RPV to RHV)

****For inpatients:** If a recent abdominal ultrasound was done on the patient in the last 72 hours and an abdomen doppler is ordered, all images of the liver, biliary system, spleen and an assessment for collaterals and ascites should still be performed in addition to the liver dopplers requirements.

****If a patient is coming in for pain,** document within the indication section what the current status of pain is. For instance, how long the patient has had pain, if it's getting worse or better, and where exactly the pain is. Always take an image where the patient is hurting the most, labeled as area of pain. When describing the pain, write "per patient, ..." in the indication. Example: Per the patient, his pain is now in the RUQ and getting worse.

****"Not well seen"** to be stated if structure is not able to be completely evaluated. Include the reason why in relevant section of the report.

****Any masses, cysts, stones or abnormalities** should be measured in three dimensions and have a 2D picture and a color image documented. MFI should be routinely used to evaluate perfusion and low flow structures as needed. Measure the 2 largest or most worrisome masses/cysts in any given structure and comment on the presence of additional if relevant.

****Cine clips** to be added as needed for any abnormality seen.

IMAGES TO OBTAIN

PANCREAS *subcostal/epigastric approach*

Transverse images:

- Pancreas head, body, and tail.
- Pancreatic head showing porto-splenic confluence.
- Pancreatic body showing splenic vein
- Pancreatic body showing splenic vein with color
- Document and measure pancreatic duct if visible.

Sagittal images:

- Pancreatic head, body, and tail.

Take image of "Pancreas Area" if not well seen.

LEFT LIVER - *subcostal/epigastric approach*

Sagittal images:

- Left lobe with left portal vein and ligamentum teres.
- Left lobe with hepatic vein
- Cine clip sweeping through LHL in sagittal from medial to lateral

Transverse images:

- Left lobe visualizing dome of liver
- Left hepatic vein confluence into IVC with and without color
- Left lobe at left portal vein with and without color assessing for thrombus and direction of flow
- Cine clip sweeping through LHL in transverse from superior to inferior

CAUDATE LIVER - *subcostal/epigastric approach*

- Sagittal image of the caudate lobe.
- Transverse image of the caudate lobe.

RIGHT LIVER - *subcostal or intercostal approach*

Transverse images:

- Right lobe to visualize dome of liver
- Right and middle hepatic veins confluence into IVC with and without color
- Right lobe at right portal vein with and without color assessing for thrombus and direction of flow
- Right lobe and right kidney
- Cine clip sweeping through RHL in transverse from superior to inferior

Sagittal images:

- Right hemidiaphragm to assess for pleural effusions and ringdown.
- Right lobe and right portal vein
- Main interlobar fissure with gallbladder CHD and MPV
- Right lobe showing echotexture between liver and right kidney.
- Right lobe and right kidney documenting approximate liver size. Measurement of length of the liver is not needed unless requested.
- Cine clip sweeping through RHL in sagittal from medial to lateral

NOTE: If lateral edge or dome of liver is not seen in its entirety with patient in supine position, turn patient in LLD or raise head of bed and repeat RHL cine clips to visualize better.

MAIN PORTAL VEIN -

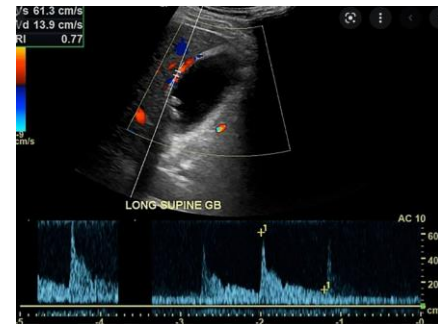- 2D image through MPV evaluating for thrombus
- Color image of MPV showing patency, filling and direction of flow

BILE DUCTS

- Sagittal image of CBD and CHD with measurements at the level of the porta hepatis. Color doppler should be used to distinguish ducts from vessels.
- If dilated, follow CBD as distal as possible to look for stones/mass and measure as distal as possible as well.
- Document and measure any intrahepatic bile duct dilatation with 2D and color imaging.

GALLBLADDER

- Sagittal image
- Transverse image
- Measurement of gallbladder wall in sagittal section only. Do not include liver surface. If liver edge is edematous, try to measure free GB wall. Normal wall thickness is <3mm.
- Take image and cine through GB if there is any abnormality (stones, polyp, adenomyomatosis.)
- Take color image of any mass seen.
- LLD POSITION: Transverse and sagittal image of gallbladder with patient in LLD position to check for stones/polyps and mobility.
- If evaluating for cholecystitis, or if suspicious GB findings such as thickened wall or distension:
 - Evaluate for Murphy's sign and include in the report.
 - Gallbladder length measurement. Normal <8cm
 - Color doppler of gallbladder wall to assess for hypervascularity
 - Spectral doppler velocity of the cystic artery which can be seen within wall of anterior gallbladder.
 - Normal velocity <40cm/s
 - If artery cannot be visualized, include color doppler of area and comment in report that it could not be seen.
 - Add code UORGDL if cystic artery is sampled.



RIGHT KIDNEY

- Sagittal image of right kidney in medial, middle, and lateral views.
- Sagittal measurement of right kidney.
- Transverse images of superior, mid, inferior right kidney.
- Demonstrate calculi, hydronephrosis or pelviectasis with a color image of the renal pelvis if present.
- **IF RENAL STONES ARE PRESENT:**
 - Measure renal stones in one largest dimension.
 - Demonstrate acoustic shadowing if possible.
 - Image with color to look for twinkle (can still be a stone if no twinkle shows).
- **IF HYDRONEPHROSIS, PELVIECTASIS, OR DILATED URETER PRESENT:**
 - Patient should void bladder and images should be taken to reassess degree of dilation with 2D and color images.

SPLEEN

- Sagittal and transverse images through spleen
- Sagittal length measurement of spleen
- Color Doppler image of any abnormality.

ASSESS FOR COLLATERALS

- Color image documenting any collaterals or varies if present in periportal area, LUQ, epigastric region, or the presence of a recanalized umbilical vein. If collaterals are seen, the splenic vein velocity and direction of flow should be documented.

LOWER QUADRANTS:

- Document RLQ and LLQ to check for ascites.

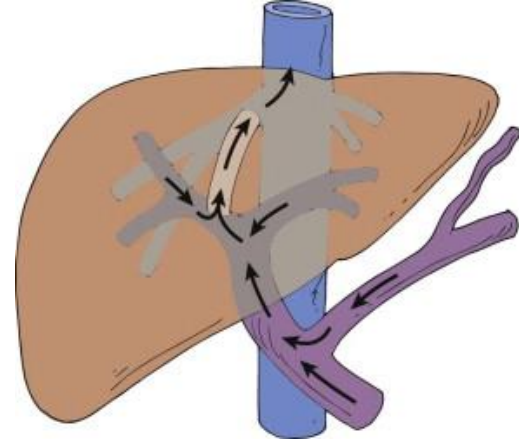
COLOR & SPECTRAL DOPPLER IMAGES TO OBTAIN

SWEEP SPEED should be set to SLOW (36cm/s) on the Philips machines and 2 or 3 on the GE machines.

You will be asked to repeat images if this is not the case. It is critical for comparison to priors to have the settings consistent.

PORTAL VEINS - LPV, RPV, MPV **VELOCITY with angle correction**

- Color images of MPV, Right PV and Left PV showing direction of flow.
- MPV direction of flow should be **hepatopetal**
- RPV and LPV direction of flow should be **hepatofugal**. PV flow should be headed towards TIPS, not into the liver. Hepatopetal flow, or very low flow, in the RPV or LPV suggests TIPS dysfunction.
- Mild undulation or phasicity in the waveform is normal and can be seen especially if the patient is thin or has eaten a large meal recently.
- A pulsatile portal vein is defined as one that has >50% variation in velocities between the minimum and maximum velocity within the waveform. This can be seen with right heart failure, tricuspid regurge, HV and PV fistula, PHTN, malignant tumor invasion, and cirrhosis.
- Normal MPV velocity is >30-60 cm/s
- Normal RPV and LPV velocity is >10cm/s.
- Velocity should always be measured with angle correction.



TIPS- PROX, MID, DIST **VELOCITY with angle correction**

- Color images of TIPS showing direction of flow and looking for areas of filling defects or color aliasing
- TWO angle corrected velocity measurements at each location - Prox (PV end), Mid, Dist (HV end)
 - One velocity measurement with color doppler
 - One velocity measurement without color doppler
- Normal TIPS velocity ranges –
 - Between 190cm/sec - 50 cm/sec
 - Abnormal if velocities increase more than 60 cm/sec from baseline or decrease more than 40 cm/sec from baseline.

HEPATIC ARTERY - LHA, RHA, PHA **RESISTIVE INDEX with angle correction**

- Measurement of RI with angle correction, showing a linear segment of the artery.
- Normal RI range is 0.5 -0.8

HEPATIC VEINS - LHV, RHV, MHV **WAVEFORM ONLY**

- Document waveform and assess for phasicity.
- Sample should be taken within 2 cm from IVC
- LHV can often be difficult to separate from artifact from heart motion, it is okay to come farther out into liver if needed to eliminate doppler artifact.
- Velocity is not needed except for in cases where color flow is seen aliasing, or a narrowing is suspected.
- Phasicity of the hepatic veins should be assessed during normal respiration. Deep inspiration may dampen hepatic flow. If necessary, use suspended/mid respiration or shallow breathing.
- If monophasic waveforms are seen, use LLD positioning to reassess. This can sometimes be positional and due to compression.
- Hepatic Vein that the TIPS empties into can often be hard to see, if this is the case say it is not well seen.

INFERIOR VENA CAVA – IVC **VELOCITY with angle correction**

- Color image of IVC
- Velocity with spectral doppler and angle correction

SPLenic VEIN – **VELOCITY with angle correction**

- Color image of the splenic vein at the pancreas showing direction of flow.
- Splenic vein at splenic hilum - angle corrected velocity measurement. If patient has had a splenectomy no spectral is needed

TIPS ABDOMEN DOPPLER ULTRASOUND IMAGE LIST

IMAGE	MODE	IMAGE	MODE
Panc Trans H/B/T	2D	TIPS Prox/Mid/Dist <i>without color</i>	2D
Panc Sag H/B/T	2D	TIPS Prox/Mid/Dist <i>w/ color</i>	Color
Splenic Vein at panc	Color	TIPS Prox <i>velocity w angle correction, w color</i>	Spectral cm/s
<i>Panc Duct if dilated</i>	<i>2D +</i>	TIPS Prox <i>velocity w angle correction, no color</i>	Spectral cm/s
		TIPS Mid <i>velocity w angle correction, w color</i>	Spectral cm/s
Left Liver Sag (at portal vein)	2D	TIPS Mid <i>velocity w angle correction, no color</i>	Spectral cm/s
Left Liver Sag (at hepatic vein)	2D	TIPS Dist <i>velocity w angle correction, w color</i>	Spectral cm/s
Left Liver Sag M-L	Cine	TIPS Dist <i>velocity w angle correction, no color</i>	Spectral cm/s
Caudate Liver Sag	2D		
Caudate Liver Trans	2D	GB Sag	
Left Liver Trans (at hepatic vein)	2D	GB Wall w/measurement	2D+
Left Liver Trans (at portal vein)	2D	GB Sag w/ color	Color
Left Liver Trans S-l	Cine	GB Trans	2D
LPV <i>without color</i>	2D	GB Sag LLD	2D
LPV <i>w/ color</i>	Color	GB Trans LLD	2D
LPV <i>velocity w angle correction</i>	Spectral cm/s	<i>GB length if r/o chole</i>	<i>2D+</i>
LHA RI <i>w angle correction</i>	Spectral RI	<i>Cystic duct if r/o chole</i>	<i>Spectral</i>
LHV <i>waveform</i>	Spectral		
		CHD w/measurement and color	Color+
Right Liver Trans (at dome)	2D	CBD w/measurement and color	Color+
Right Liver Trans (at hepatic veins)	2D		
Right Liver Trans (at portal vein)	2D	Right Kidney Sag Mid	2D
Right Liver Trans (at RK)	2D	Right Kidney Sag Mid w/ measurement	2D +
Right Liver Trans S-l	Cine	Right Kidney Sag Med	2D
Right Liver Sag/Rt Chest	2D	Right Kidney Sag Lat	2D
Right Liver Sag (at portal vein)	2D	Right Kidney Trans Sup	2D
Right Liver Sag (at main lobal fissure)	2D	Right Kidney Trans Mid	2D
Right Liver Sag / RK	2D	Right Kidney Trans Inf	2D
Right Liver Sag L-M	Cine		
		Spleen Sag x2	2D x2
MPV <i>without color</i>	2D	Spleen Sag w/ measurement	2D +
MPV <i>w/ color</i>	Color	Spleen Trans	2D
MPV <i>velocity w angle correction</i>	Spectral cm/s	Splenic Vein	Spectral cm/s
PHA RI <i>w angle correction</i>	Spectral RI		
RPV <i>without color</i>	2D	RLQ	2D
RPV <i>w/ color</i>	Color	LLQ	2D
RPV <i>velocity w angle correction</i>	Spectral cm/s		
RHA RI <i>w angle correction</i>	Spectral RI	Assess for collaterals	Color, 2D+
MHV <i>waveform only unless stent</i>	Spectral		
RHV <i>waveform only unless stent</i>	Spectral	<i>For cirrhosis/HCC screening: Capsule</i>	<i>Linear</i>
IVC <i>velocity w angle correction</i>	Spectral cm/s		
		<i>SOS/VOD: Elasto of liver if requested</i>	<i>Elasto</i>
		<i>MFI for lesions</i>	<i>MFI</i>

LIVER TIPS ABDOMEN DOPPLER PROTOCOL HISTORY

	Date	Changes made	By whom
Updated	10/25/2021		Becky Marion
Updated	03/03/22	-Added color of SV at pancreas -Added Spectral of SV at hilum -Added measure size of HVs for Budd Chiari -Added angle correction for HAs w length of artery shown -Removed pelvis/bladder area images -Created separate TIPS, PHT, PVT protocols -Changed NPO requirement to 2-6 hrs	03/03/22 Protocol Meeting Attendees Dighe, Lee, Kolokythas
Approved	3/14/2022		Manjiri Dighe
Added	5/4/2022	Elastography for VOD	Renee Betit Fitzgerald
Added	10/10/2022	Cystic duct and GB length for cholecystitis c	Renee Betit Fitzgerald
Added	10/27/2022	Cine sweeps of RHL &LHL in trv and sag	Renee Betit Fitzgerald
Removed	3/1/2024	Elastography no longer needed for SOS/VOD unless requested	Manjiri Dighe
Added	4/15/2024	Image list	Renee Betit Fitzgerald
Reviewed	6/27/2024	-Added: "For inpatients: If a recent abdominal ultrasound was done on the patient in the last 72 hours and an abdomen Doppler is ordered, a liver, spleen and doppler only study can be performed unless there are other areas are of interest in addition." -Added: Assess for collaterals	Protocol Meeting Attendees: Manjiri Dighe, Shaun Bornemeier, Dalene Edden, Renee Betit Fitzgerald, Becky Marion