

BASIC AND DETAILED ANATOMY OBSTETRICAL ULTRASOUND PROTOCOL

GESTATIONAL AGE: 18w0d to term

BILLING CODES:

UOB2- Basic singleton pregnancy (76805)
 UOBC- Detailed singleton pregnancy (76811)
 UOBTWINC (76811 & 76812 for additional fetus)
 UOBTRIPC (76811 & 76812 x2 for additional fetuses)
 UOBTV to be added when transvaginal exam is performed.

PATIENT PREP: Full bladder

DESCRIPTION: This exam is to be used for initial anatomic survey studies in the 2nd or 3rd trimester. A Basic Anatomy study is performed on standard risk patients. A Detailed Anatomy study is performed on patients or pregnancies meeting high-risk criteria including twins/multiples, BMI ≥30, AMA, diabetic, or if an abnormality is seen while doing a Basic Anatomy exam. Review a comprehensive list of indications for Detailed Anatomy [here](#).

**** See separate protocols for OB Follow Up, OB Limited exams and specialty OB exams and TTTS/ TAPS protocol for mono-di and mono-mono pregnancies.**

****See Umbilical Artery Doppler should be performed beginning at 23 weeks if the EFW or AC is ≤ 10%**

**** See minimum additional images for FL or HL that measures ≤2%. If indicated after these images are obtained, a referral will be made to MFM for further evaluation and full skeletal dysplasia survey.**

****Microcephaly protocol should be performed when the HC is ≤ 2%**

****If an early anatomy survey was completed before 18w0d, all anatomy images need to be repeated.**

****If a patient has not been seen within our system and is referred to us for a limited exam or for growth, the provider must indicate where the anatomy study was completed and be clear that we do not need to repeat it. If the anatomy study was not completed at the outside facility, we cannot do a partial anatomy survey completion and must repeat our own basic or detailed anatomy assessment if asked to follow up on unseen anatomy. If asked to assess a fetal abnormality and an anatomy study is not ordered, consult with reading MFM physician about the case to determine depth of study to be done.**

DATING: As a routine, use the date provided by the clinician or patient's known LMP. Working EDD in EPIC should be used if more than one date is provided. Use AIUM and ACOG dating criteria if dating is unknown. Guidelines for redating based on ultrasound can be found [here](#)

IMAGES TO OBTAIN

Additional images may be requested as needed in addition to the basic requirements listed below.

MATERNAL STRUCTURES

UTERUS:

- Transverse images – Fundus, Mid and LUS
- Sagittal images – Right, Mid and Left
- If fibroids are present, measure the 2 largest/most significant. Fibroids located in the LUS should always be included due to potential delivery complications.
- For multiples, on each uterus image, label the location of fetuses with A, B etc.

MATERNAL STRUCTURES CONTINUED...

ADNEXA:

- Right and left adnexal regions in transverse and sagittal views

OVARIES:

- Sagittal image of right and left ovary with and without measurements
- Transverse image of right and left ovary with and without measurements

CERVIX:

TRANSABDOMINAL IMAGING

- To be measured transabdominally on all pregnancies less than 24 weeks GA. Normal cervical length is greater than 3.0 cm before 24 weeks.
- Color Doppler image of the LUS to assess for vasa previa.
- If you suspect vessels are present or are unable to see the cervix without fetal parts obscuring the area, a transvaginal imaging study should be performed.

TRANSVAGINAL IMAGING

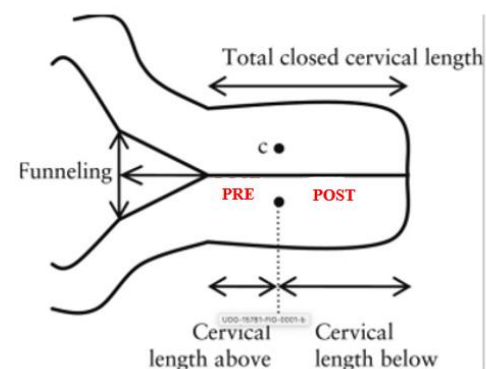
STERILE OR BACTERIOSTATIC GEL PACKS AND SINGLE USE COVERS TO BE USED FOR ALL TRANSVAGINAL IMAGING.

*****Verbal consent to be obtained from the patient for transvaginal imaging. Documentation of consent to be included in report. If a male sonographer is doing the scan, there will need to be a female chaperone present for the transvaginal or translabial portion of the exam.**

- If the cervix appears shortened or funneled before 24 weeks, or if a cervical length is specifically requested, a transvaginal ultrasound should be performed. (A translabial study can be done in place of transvaginal imaging in cases of PPRM, bulging membranes or patient request/refusal of TV.)

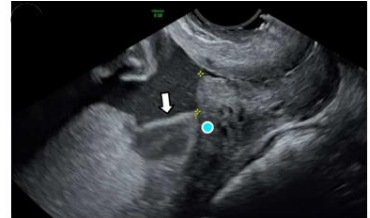The following should be documented on transvaginal -

- Total cervical length
- Closed length of cervix
- Open length of funneling if present. Greater than 50% open length of cervix is associated with higher risk of preterm delivery.
- Observe for dynamic changes for at least 2 minutes. Images should be taken at the beginning and end of this period to document the time spent. If the cervix is dynamic, report the shortest closed cervical length.
- Color Doppler image of the LUS to assess for vasa previa. Sample any vessels seen within 2cm of the cervical os with spectral Doppler to see if they are arterial or venous. If it is an arterial vessel, be sure to also include heart rate measurements to differentiate the fetal blood vessels from maternal vessels by comparing their respective heart rates.
- Transvaginal ultrasound is not needed to evaluate the cervix after 24 weeks. If you find a short or dilated cervix transabdominally during an ultrasound exam, contact the referring provider and inform them of the findings. If the referring provider cannot be contacted, call triage nurse or L&D.
- For cerclage evaluation: Take 2D images, as well as cine sweeps, of the cervix showing suture in transverse and sagittal. Measure the total cervical length AND closed cervical length from stitch to external os. Do not apply fundal pressure or Valsalva with patients that have a cerclage.



PLACENTA:

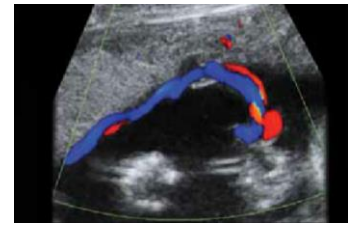
- Document location of placenta in sagittal and transverse.
- Show thickness and echotexture.
- If venous lakes are present, include a color image and a 2D cine clip showing the slow flow movement within.
- Assess for a bi-lobed placenta or succenturiate lobe. If present, document location of connecting vascular supply to the primary placental lobe.
- Assess relationship of placental edge to the internal cervical os to rule out placenta previa.
- Measure the distance from the inferior most portion of the placental tissue if it appears to be low lying. Also include a measurement from the edge of the placental sinus if one is present. A placenta should be described as low lying if the placental tissue is less than 2 cm, or if the sinus is less than 1.1 cm, from the internal cervical os.
- Cine clip of any abnormality.
- If accreta is suspected, see additional images needed in separate PAS protocol.



Measurement from a placental sinus to internal os.

PLACENTAL CORD ORIGIN:

- Document the cord origin at the placenta in transverse and sagittal planes using color Doppler and show the vessels of the cord separating into the placenta. To rule out a velamentous cord origin, the cord should be shown clearly coming out from the placenta, not just coursing along the surface.
- Measure the distance from the cord origin to the edge of the placenta if it appears near the edge. A marginal cord origin is defined as being less than 2 cm from placental edge.



FETAL HEART RATE:

- Measure fetal heart rate with M-Mode. Normal range is 110 – 170 bpm. If the fetal heart rate is above or below, refer to Urgent OB Contact List to contact charge nurse or L&D. If being scanned at an outpatient clinic, contact the referring provider or on call the OB staff for further instructions.

FETAL POSITION:

- Document fetal position.

FETAL SITUS:

- With a dual screen image, demonstrate fetal situs. In a transverse view of the abdomen and chest, show side-by-side images of the fetal stomach and 4CH heart on the left side of the fetus's body.
- If the fetus has changed position since presentation was first documented, show the new presentation of fetus to confirm which side is the left side of body.

AMNIOTIC FLUID VOLUME:

- 20-24 weeks: AFI evaluation should be done using MVP. If abnormal, obtain a four quadrant AFI.
- After 24 weeks, or if it appears abnormal before 24 weeks: Evaluation should be done using a four quadrant AFI
- For multiple gestations (twins, triplets, etc): Always measure the MVP unless Mono/mono gestation, then use four quadrant measurements.
- Fluid pockets measured should be greater than 1cm in width.

AMNIOTIC FLUID INDEX 4 quadrant

<5cm	Oligohydramnios
5-24 cm	Normal
≥ 24 cm	Polyhydramnios

MVP and TWINS single largest pocket

<2 cm	Oligohydramnios
2-8 cm	Normal
≥ 8 cm	Polyhydramnios

BIOMETRY: Measure each of the following at 2-3 times:

BPD –measured on an axial plane that traverses the thalami and CSP

HC – include in image with BPD. **If HC ≤ 2%,** see Microcephaly protocol

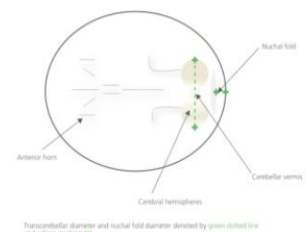
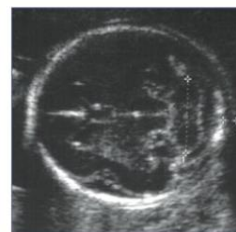AC - Transverse image through the upper abdomen at the level of the fetal stomach, umbilical vein and portal sinus.

Humerus - See additional image requirements at end of protocol if **HL measures ≤2%**

Femur - See additional image requirements at end of protocol if **FL measures ≤2%**

HEAD AND NECK:

- BPD/HC measured 2-3 times in axial plane that traverses thalami and CSP
- Lateral ventricles with measurements (normal < 10mm)
- Cisterna Magna with measurements (normal < 10mm)
- Cerebellum with transverse diameter
- Cerebellar vermis
- Falx
- Cavum Septi Pellucidi (CSP) – if not well seen, obtain color Doppler image of the Pericallosal arteries
- Choroid Plexus
- Nuchal fold - measurement at the level of cerebellum measured on a separate image from CM. Normal is <6mm between 15-22 wks. If the nuchal looks thick after 22 weeks, then still include a measurement.
- Integrity and shape of the cranial vault/calvarium
- Cine clip sweeping superior to inferior through the entire head showing structures of the brain.
- ****If clinically indicated:** Brain parenchyma, 3rd Ventricle, 4th Ventricle, Corpus Callosum, and Pericallosal Arteries **

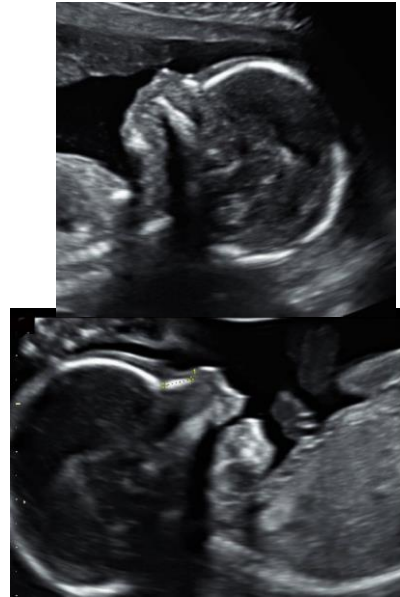

FACE:

- Profile with the nasal bone, chin and intact maxilla
- Fetal nose and lips in a coronal plane
- Fetal orbits and lens of eyes

FOR DETAILED ANATOMY SURVEYS:

- Fetal maxilla in a transverse view
- Fetal mandible in a transverse view
- Nasal bone measurement (normal >2.5mm)
- **If clinically indicated: Palate, Tongue, Ear position and Inner/ Outer Orbital Diameter**



size,

CHEST:

- Lungs in transverse view at level of 4ch heart, looking at symmetry and for presence of any mass or abnormality.

HEART:

While evaluating the fetal heart, attention should be paid to the following characteristics: **POSITION, SIZE, FUNCTION, RHYTHM, PROPORTION, INTRAVENTRICULAR SEPTATION, AND ORIENTATION OF THE GREAT VESSELS.**

HEART VIEWS REQUIRED:

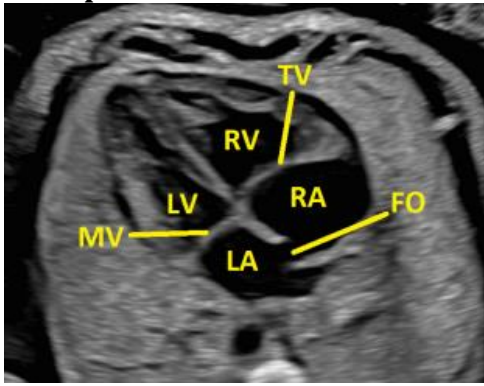
- 4-chamber view which includes view of entire chest to assess size and position
- 4-chamber view that is zoomed in on the heart.
- 4-chamber view of heart showing the intraventricular septum (IVS) perpendicular to the ultrasound beam.
- 4-chamber with color Doppler
- Lt ventricular outflow tract in a 5-chamber view to show the relationship of the aorta to the intraventricular septum
- Right ventricular outflow tract, showing branching of the pulmonary arteries
- 3 Vessel View
- 3 Vessel Trachea
- 3 Vessel Trachea with color flow
- Cine clip in 4-chamber view showing contractility of heart.
- Cine clip of the 4-chamber view sweeping through the outflow tracks.
- Cine clip of the entire heart sweeping from base to apex, or vice versa.

FOR DETAILED ANATOMY SURVEYS:

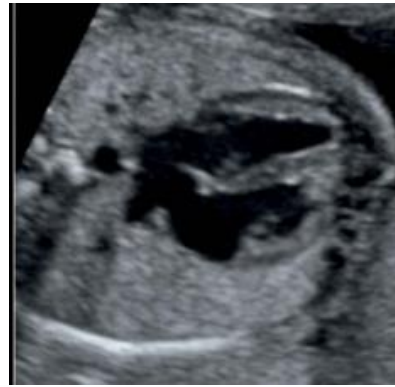- Aortic Arch (color flow images can be used as a supplement if not well seen in 2D but is not required)
- Ductal Arch (color flow images can be used as a supplement if not well seen in 2D but is not required)
- IVC and SVC

HEART IMAGE EXAMPLES: [Images courtesy of Voluson Club](#)

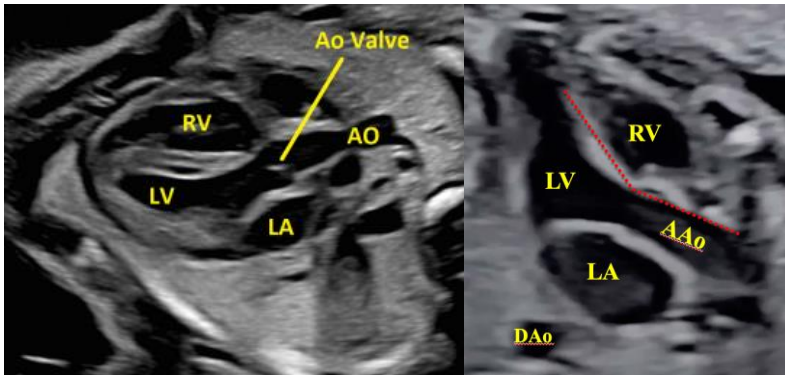
4CH Apical view:



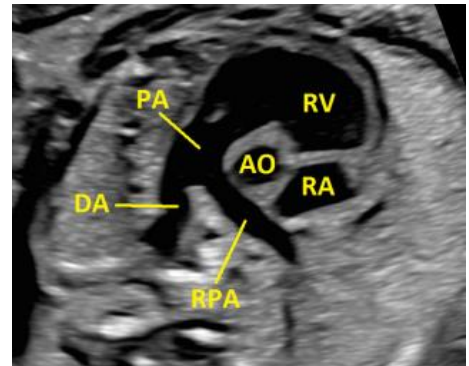
4 CH / IVS view



LVOT views

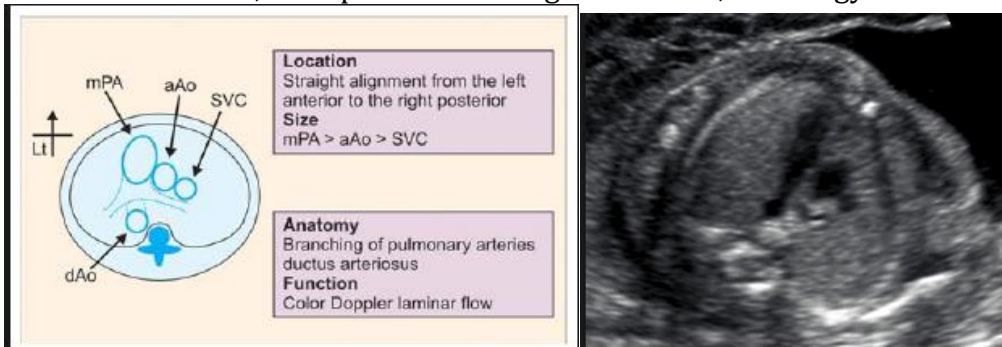


RVOT view

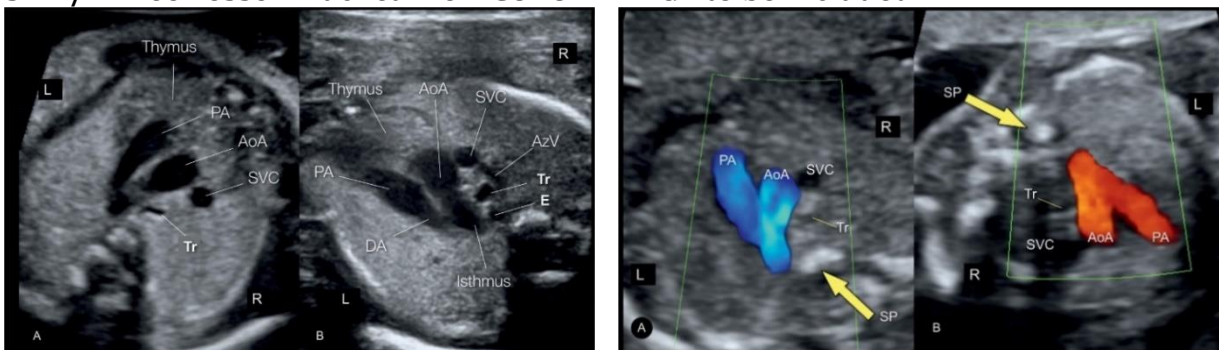


3 Vessel view (3VV):

Helps diagnose conotruncal heart defects: Examples of conotruncal defects include, but are not limited to: truncus arteriosus, transposition of the great vessels, Tetralogy of Fallot.

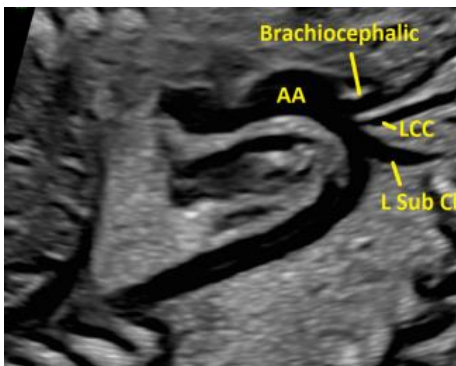


3VT / Three vessel Trachea view COLOR IMAGE to be included.

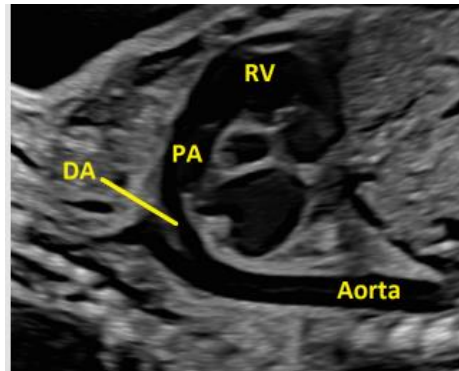


**FOR
DETAILED**

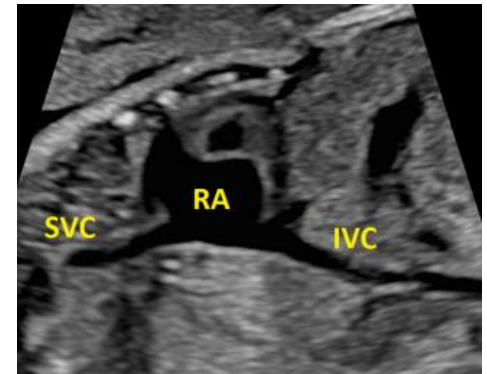
Aortic Arch



Ductal Arch



IVC/SVC



DIAPHRAGM:

- Sagittal views of the left and right sides of diaphragm.
- Cine clip through the diaphragm.

SPINE:

- 2D views of the cervical, thoracic, lumbar and sacral spine in longitudinal.
- 2D views of the cervical, thoracic, lumbar and sacral spine in transverse.
- Cine sweep in transverse from cervical spine to sacral spine

ABDOMEN:

- Measure the abdominal circumference 2-3 times using a transverse image through the upper abdomen at the level of the fetal stomach, umbilical vein and portal sinus.
- Stomach image in transverse.
- Cord insertion and anterior abdominal wall showing the abdominal wall is intact on both sides of the cord insertion.
- **If clinically indicated: Liver, Small & Large Bowel, Adrenal Glands, Gallbladder, Spleen**

KIDNEYS:

- Longitudinal kidneys with measurements, labeled Left and Right.
- Color Doppler image of Aorta and both renal arteries in a coronal pane.
- Look for ectopic kidneys if not able to see in expected location.
- Transverse picture of kidneys at the level of renal pelvis.
- Measure any pelviectasis if present in a transverse view (APRPD anterior-posterior renal pelvic diameter) and follow the UTD Classification System.

Normal: 16-27weeks 6 days APRPD <4mm

>=28weeks APRPD <7mm

A1: 16-27weeks APRDP 4 to <7mm with central calyceal dilation

>=28weeks APRDP 7 to <10mm central calyceal dilation

A2-3: 16-27 weeks APRDP >=7mm

>=28weeks APRPD >=10mm

Exceptions:

- Peripheral calyceal dilation without meeting criteria is upgraded to A2-3
- Abnormal echogenic renal parenchyma is upgraded to A2-3
- Ureter dilation without meeting criteria is upgraded to A2-3

BLADDER AND 3 VESSEL CORD:

- 2D transverse view of bladder.
- Document 3 vessel cord around bladder with color Doppler
- Include additional sagittal images of bladder if abnormal appearance

EXTREMITIES

- Measure the most anterior femur length 2-3 times
- Measure the most anterior humerus length 2-3 times. This only needs to be done once during anatomy scan at 16 weeks or greater.
- Document all long bones with proper labeling (Lt humerus, Rt R/U, etc.)—This only needs to be done once during anatomy scan at 16 weeks or greater.
- Bilateral hands – show fingers and thumb, include sweep if necessary to show all digits. Try to show at least one open hand, especially with other findings such as CPC's or increased risk of trisomy.
- Bilateral feet - show bottom of feet/footprint. Additional image and cine sweep showing the profile of foot with ankle to evaluate for club foot if it is suspected.
- See additional image requirements at end of protocol if HL or FL measure <2% .

GENITALIA:

- Document in all pregnancies. Especially important in multiple gestational pregnancies and when medically indicated.
- If fetal sex is not wanted to be known, select “Appears Normal” for the genitalia section of the report. **This field will be visible in My Chart.** If Cell Free DNA results are available, cross reference with ultrasound appearance.

****If abnormalities are seen, include additional 2D images, cine sweeps, 3D imaging and color Doppler images as needed.***

ADDITIONAL IMAGES TO BE OBTAINED AS NEEDED

UMBILICAL ARTERY DOPPLER: Perform UA Doppler as requested, or if the AC or EFW is $\leq 10\%$ after 23 weeks (current age of viability.) For multiple, regardless of chorionicity, UA Doppler should be taken for BOTH twins if one is FGR. See additional details about technique in OB Doppler Protocols.

DUCTUS VENOSUS: To be performed as requested, or if absent or reversed umbilical artery doppler is observed. See additional details about technique in OB Doppler Protocols.

PERICARDIAL EFFUSION:

- < 3 mm of fluid surrounding the fetal heart is considered normal in the 2nd and 3rd trimester.
- Pericardial effusions may be seen with hydrops or other (primarily cardiac) structural anomalies.
- Recommendations—if the effusion is 3-7 mm evaluate for hydrops, arrhythmia, or structural anomalies. In the absence of these, the finding is likely clinically insignificant.

FETAL HYDROPS ASSESSMENT: (Defined by two of the following)

- Ascites
- Integumentary edema
- Pericardial effusion
- Pleural effusion
- Placentomegaly

ADDITIONAL IMAGES AS NEEDED continued...

MULTIPLE GESTATIONS – TWINS, TRIPLETS ETC

SEE SPECIALIZED PROTOCOL FOR **TTTS AND TAPS FOR ALL MONOCHORIONIC PREGNANCIES**

DETAILED ANATOMY IMAGE REQUIREMENTS SHOULD BE DONE FOR ALL MULTIPLE GESTATIONS. IN ADDITION TO THE FOLLOWING:

UTERUS: Sagittal and transverse **cine sweeps** to show orientation of fetuses.

POSITION: Document each fetus' position within in the uterus as well as presentation

- On each uterus image, label the location of fetuses with A, B etc.
- Include description of fetus location in "Presentation" section of Viewpoint report.

MEMBRANE / CHRONICITY AND AMNIONICITY ASSESSMENT:

- Document the free-floating membrane between each fetus and ensure membrane is not adhered to fetus.
- Demonstrate membrane completely separating each fetus
- Document the thickness of membrane.
- Look for twin peak sign (diamniotic) or T-sign (monoamniotic)

PLACENTA:

- Document both placentas and determine if there are separate or shared placentas present. Show twin peak sign between placentas if visualized.
- Describe the location of each placenta

AMNIOTIC FLUID:

- Measure the deepest pocket (MVP) for each. In mono/mono pregnancies use 4 quadrants for AFI assessment.

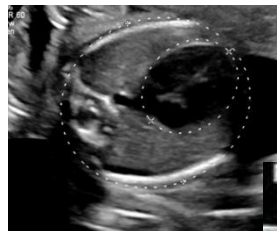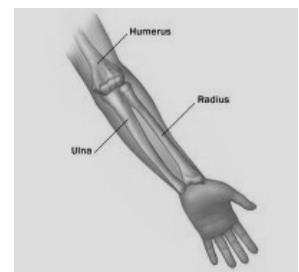
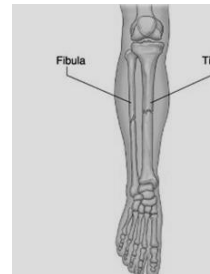
LONG BONES (FL or HL) MEASURING <2%

DETAILED ANATOMY IMAGE REQUIREMENTS IF ONLY A BASIC WAS ORDERD

MEASURE BILATERAL LONG BONES–

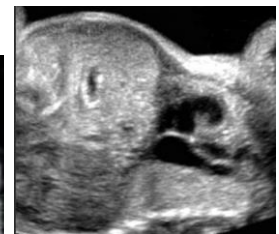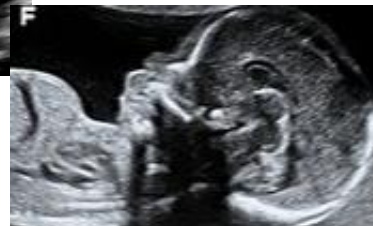Note whether long bones and skull show proper mineralization, curvatures, or fractures:

- **Femur**
- **Tibia**
- **Fibula**
- **Humerus**
- **Radius**
- **Ulna**



CHEST CIRCUMFERENCE

SAGITTAL AND CORONAL VIEWS OF CHEST showing chest size in relation to abdomen.



Bell shaped chest

If indicated, a referral will be made to MFM for further evaluation and full skeletal dysplasia survey.

ADDITIONAL IMAGES AS NEEDED continued...

HC MEASURING $\leq 2\%$ - See *Microcephaly protocol for additional info*

1. **SKULL**-Assess size, shape, sutures, and mineralization
2. **ORBITAL DISTANCE**
 - a. **Inner to inner**
 - b. **Outer to outer**
3. **CEREBELLUM**-Measured in transverse
4. **PROFILE** – Is forehead sloping or with normal contour
5. **LATERAL VENTRICLES**: (Normal is < 10 mm)
6. **CINE SWEEP** sweeping superior to inferior through the entire head showing structures of the brain.

SEE SEPARATE SPECIALIZED PROTOCOLS FOR:

- **MULTIPLE GESTATION COMPLICATIONS – TTTS/TAPS**
- **PLACENTA ACCRETA ASSESSMENT**
- **CHEST ANOMALIES:**
 - CONGENITAL DIAPHRAGMATIC HERNIA (CDH)
 - CPAM (CONGENITAL PULMONARY AIRWAY MALFORMATION)
 - PULMONARY SEQUESTRATION
- **GASTROSCHISIS/OMPHALOCELE ANOMALIES**
- **SKELETAL DYSPLASIA**
- **FETAL ARRHYTHMIA**

INDICATIONS FOR DETAILED ANATOMY SCAN

Indications for a detailed fetal anatomic examination include, but are not limited to the following conditions:

- Previous fetus or child with a congenital, genetic, or chromosomal abnormality
- Known or suspected fetal anomaly or known growth disorder in the current pregnancy
- Fetus at increased risk for a congenital anomaly, such as the following:
 - Maternal pregestational diabetes or gestational diabetes diagnosed before 24 weeks' gestation
 - Pregnancy conceived via assisted reproductive technology
 - High maternal body mass index (≥ 30 kg/m²)
 - Multiple gestations
 - Abnormal maternal serum analytes, including α -fetoprotein level and unconjugated estriol
 - Teratogen exposure
 - First-trimester nuchal translucency measurement of 3.0 mm or greater

- Fetus at increased risk for a genetic or chromosomal abnormality, such as the following:
 - Parental carrier of a chromosomal or genetic abnormality
 - Maternal age of 35 or older years at delivery
 - Positive screening test results for aneuploidy, including noninvasive prenatal testing
 - Soft aneuploidy marker noted on an ultrasound examination
 - First-trimester nuchal translucency of 3.0 mm or greater
- Other conditions affecting the fetus, including the following:
 - Congenital infections
 - Maternal drug dependence
 - Alloimmunization
 - Isoimmunization
 - Oligohydramnios
 - Polyhydramnios
- Suspected placenta PAC or risk factors for PAS such as placenta previa in the third trimester or a placenta overlying a prior cesarean scar site

Comprehensive list of indications for Detailed Anatomy Scan here:

[AIUM Detailed Fetal Anatomic Ultrasound Examination ICD-10 Indications](#)

[SMFM Coding ICD-10 indications for Detailed Anatomy](#)

OB DETAILED ANATOMY ULTRASOUND IMAGE LIST

IMAGE	MODE	IMAGE	MODE
GENERAL		CHEST	
Presentation	2D	Lungs	2D
FHR	Mmode	Rt Diaphragm	2D
Situs	Dual	Lt Diaphragm	2D
AFI (MVP for 20-24wks, 4 quad >24wks)	2D+	Diaphragm Cine R-L	Cine
MATERNAL		HEART	
Uterus Sag Mid	2D	4CH	2D
Uterus Sag Right	2D	4CH cine showing contractility	Cine
Uterus Sag Left	2D	4CH w color	Color
Uterus Trans Sup	2D	LVOT	2D
Uterus Trans Mid	2D	RVOT	2D
Uterus Trans Inf	2D	3VV	2D
Rt Adnexa Trans	2D	3VT w & w/o color	2D & color
Rt Adnexa Sag	2D	Intraventricular Septum	2D
Rt Ovary Sag w/ & w/o measurements	2D+	Heart Cine S-I	Cine
Rt Ovary Trans w/ & w/o measurements	2D+	Ductal Arch	2D
Lt Adnexa Trans	2D	Aortic Arch	2D
Lt Adnexa Sag	2D	IVC/SVC	2D
Lt Ovary Sag w/ a& w/o measurements	2D+	ABDOMEN	
Lt Ovary Trans w/ & w/o measurements	2D+	AC x3	2D+ x3
Cervix	2D+	Stomach	2D
LUS w color	Color	Kidneys Trans	2D
PLACENTA		Rt Kidney Sag w/ measurement	2D+
Placenta Edge / CVX Sag w/ meas if <2cm	2D	Lt Kidney Sag w/ measurement	2D+
Placenta Sag x2	2D	Renal arteries w/color	Color
Placenta Trans x2	2D	Bladder	2D
Cord Origin Sag	2D	3VC w/ color	Color
Cord Origin Trans	2D	Cord insertion	2D
HEAD		Genitalia	2D
BPD/HC x 3	2D+	<i>If clinically indicated: Liver, Small & Large Bowel, Adrenal Glands, Gallbladder, Spleen</i>	
Lateral Ventricle w/ measurement	2D+	SPINE	
Choroid Plexus	2D	Spine Sag	2D
Cavum Septum Pellucidum	2D	C Spine Trans	2D
Falx	2D	T Spine Trans	2D
Cerebellum w/ measurement	2D+	L Spine Trans	2D
Cisterna Magna w/ measurement	2D+	S Spine Trans	2D
Vermis	2D	Spine Trans cine C-S	Cine
Head Cine S-I	Cne	UPPER EXTREMITIES	
Nuchal Fold w/ measurement	2D+	HL x3	
<i>If clinically indicated: Brain parenchyma, 3rd Ventricle, 4th Ventricle, Corpus Callosum, and Pericallosal Arteries</i>		Rt Humerus Lt Humerus	
FACE		Rt R/U Lt R/U	
Profile	2D	Rt Hand Lt Hand	
Nasal Bone w/ measurement	2D+	Open Hand	
Nose/Lips	2D	LOWER EXTREMITIES	
Orbits	2D	FL x 3	
Maxilla	2D	Rt Femur Lt Fem	
Mandible	2D	Rt T/F Lt T/F	
		Rt Foot Lt Foot	
<i>If clinically indicated: Palate, Tongue, Ear position and size, Inner/ Outer Orbital Diameter</i>		ADDITIONAL IMAGES IF NEEDED	
		ALL LONG BONES & Chest Circ if FL or HL <2%,	

OB BASIC ANATOMY ULTRASOUND IMAGE LIST

IMAGE	MODE
GENERAL	
Presentation	2D
FHR	Mmode
Situs	Dual
AFI (MVP for 20-24wks, 4 quad >24wks)	2D+
MATERNAL	
Uterus Sag Mid	2D
Uterus Sag Right	2D
Uterus Sag Left	2D
Uterus Trans Sup	2D
Uterus Trans Mid	2D
Uterus Trans Inf	2D
Rt Adnexa Trans	2D
Rt Adnexa Sag	2D
Rt Ovary Sag w/ & w/o measurement	2D+
Rt Ovary Trans w/ & w/o measurements	2D+
Lt Adnexa Trans	2D
Lt Adnexa Sag	2D
Lt Ovary Sag w/ & w/o measurements	2D+
Lt Ovary Trans w/ & w/o measurements	2D+
Cervix	2D+
LUS w color	Color
PLACENTA	
Placenta Edge / CVX Sag w/ measurement if <2cm	2D
Placenta Sag x2	2D
Placenta Trans x2	2D
Cord Origin Sag	2D
Cord Origin Trans	2D
HEAD	
BPD/HC x 3	2D+
Lateral Ventricle w/ measurement	2D+
Choroid Plexus	2D
Cavum Septum Pellucidum	2D
Cerebellum w/ measurement	2D+
Cisterna Magna w/ measurement	2D+
Head Cine S-I	Cine
Nuchal Fold w/ measurement	2D+
FACE	
Profile	2D
Nose/Lips	2D
Orbits	2D
CHEST	
Rt Diaphragm	2D
Lt Diaphragm	2D
Diaphragm Cine R-L	Cine

IMAGE	MODE
HEART	
4CH	2D
4CH cine showing contractility	Cine
4CH w color	Color
LVOT	2D
RVOT	2D
3VV	2D
3VT	2D
3VT w/ color	Color
Intraventricular Septum	2D
Heart Cine S-I	Cine
ABDOMEN	
AC x3	2D+
Stomach	2D
Kidneys Trans	2D
Rt Kidney Sag w/ measurement	2D+
Lt Kidney Sag w/ measurement	2D+
Renal arteries w/color	Color
Bladder	2D
3VC w/ color	Color
Cord insertion	2D
Genitalia	2D
SPINE	
Spine Sag	2D
C Spine Trans	2D
T Spine Trans	2D
L Spine Trans	2D
S Spine Trans	2D
Spine Trans cine C-S	Cine
UPPER EXTREMITIES	
HL x3	2D+
Rt Humerus Lt Humerus	2D
Rt R/U Lt R/U	2D
Rt Hand Lt Hand	2D
+Open Hand	
LOWER EXTREMITIES	
FL x 3	2D+
Rt Femur Lt Fem	2D
Rt T/F Lt T/F	2D
Rt Foot Lt Foot	2D
ADDITIONAL IMAGES IF NEEDED	
<i>ALL LONG BONES & Chest Circ if FL or HL <2%,</i>	
<i>ADD DETAILED VIEWS IF ANY ABNORMALITY SEEN</i>	
<i>Falx Vermis</i>	
<i>Nasal Bone w/ measurement</i>	
<i>Maxilla Mandible</i>	
<i>Lungs</i>	
<i>Ductal Arch Aortic Arch IVC/SVC</i>	

REFERENCES:

- AIUM Case Requirements 76811.pdf
- AIUM 2nd Trimester Detailed Anatomy Practice Parameters Image Library
- Voluson Club Fetal Heart Poster-Global.indd

OB BASIC AND DETAILED ANATOMY PROTOCOL HISTORY

	Date	Changes made	By whom
Updated	3/12/2021		Becky Marion
Updated		Color of 3VT added	Renee Betit Fitz
Updated	5/1/2022	Format Changed and General info added Took out : -Valsalva/Fundal Pressure for cervix eval -3VC in fluid -Sagittal images of Maxilla and mandible - sagittal images of bladder unless indicated Added : -Cine Sweeps of cerclage & measurement info -Dual Screen for situs and additional presentation image if position changed -4ch heart cine sweep to show contractility -Image of IVS showing septum -Updated heart image examples -Clarified hand and feet image requirements -Genitalia section updated. -Multiples section updated to reflect images we take -UA/MCA sections added from "Doppler statement" -Hydrops section added -Precrcta section details added -Anomalies made into separate protocols -Indications for Detailed added	4/28/2022 Protocol Review Meeting. Attending physicians present Dighe, Cheng, Ma Updates done by Renee Betit Fitzgerald
Approved	5/5/2022		Manjiri Dighe
Added	10/25/2022	Placenta Accreta Protocol List 1-10 Cine clip from base to apex of heart Cine clip of head/brain sup to inf	Renee B Fitz
Changed	12/12/22	If anatomy was cleared before 17 weeks 0 days, all anatomy images need to be repeated except extremities.	Renee B Fitz
Added	1/31/2023	Added to align w AIUM standards: Basic – 3VT views Detailed – Falx, vermis, lungs, NB with meas	
Added	1/31/2023	Added agreed on AFI chart	Manjiri Dighe Edith Cheng Renee Betit Fitz
Changed	5/5/2023	Cerclage image was incorrect. Pre and Post labels revised. Removed Placenta Accreta section – see specialized protocol	OB Protocol meeting 4/2723 Dighe, Cheng, Ma, Hitti, Shaun, Renee, Dalene
Added	5/23/2023	If anatomy cleared on or after 17w0d it does not need to be repeated.	Manjiri Dighe
Copied		Skeletal dysplasia protocol parameters added to intro	

OB BASIC AND DETAILED ANATOMY PROTOCOL HISTORY continued...

	Date	Changes made	By whom
Changed	10/28/2023	New nuchal thickness criteria 16-22wks <6mm Measure NF until 22wks and after if appears thickened. Nasal bone - normal >2.5mm	OB Protocol meeting 6/27/23 Dighe, Cheng, Ma, Shaun, Renee, Dalene, Becky
Change	7/25/2024	Added 1.1cm for cut off of low lying from placental sinus Workflow change: Due to time restraints, patients will be referred to MFM for full skeletal dysplasia survey and workup if short long bones are incidentally seen on routine imaging. Minimum images to still obtain are: Bilateral long bones, chest circumference, sagittal image of chest. Detailed anatomy views if a basic was ordered	Combined Protocol Meeting MFM/RAD Attendees: M. Dighe, E. Cheng, J. Hitti, M. Richley, S Bornemeier, B. Marion, R. Betit Fitzgerald
Added	1/23/2025	Added AFI MVP for 20-24wks, do 4 quadrant AFI if abnormal.	Combined Protocol Meeting MFM/RAD Attendees: 1/23/25 E Cheng, M Dighe, K Ma, M Richley, S Swati, C Cheng, S Bornemeier, B Marion, R Betit Fitzgerald, P Thompson
Added	2/12/2025	Added: CERVIX - A translabial study can be done in place of transvaginal imaging in cases of PPRM, bulging membranes or patient request/refusal of TV. -Assess whether the cervix is dynamic by observing for changes for at least 2 minutes. -Color image of the LUS to assess for vasa previa. -Sample any vessels seen within 2cm of the cervical os with spectral Doppler to see if they are arterial or venous. If it is an arterial vessel, be sure to also include a HR measurement to differentiate the fetal blood vessels from maternal vessels by comparing their respective heart rates. PLACENTA -If venous lakes are present, include a color image and a 2D cine clip showing the slow flow movement within. -Assess for a bi-lobed placenta or succenturiate lobe. If present, document location of connecting vascular supply to the primary placental lobe. -Document the placental cord origin in transverse and sagittal planes using color Doppler and show the vessels of the cord separating into the placenta. To rule out a velamentous cord origin, the cord should be shown clearly coming out from the placenta, not just coursing along the surface. Added: Cavum Septi Pellucidi (CSP) – if not well seen, obtain color Doppler of Pericallosal Arteries	Manjiri Dighe Renee Betit Fitzgerald

OB BASIC AND DETAILED ANATOMY PROTOCOL HISTORY continued...

Added	4/30/2025	If HC measuring $\leq 2\%$, see additional image requirements and Microcephaly Protocol	Protocol meeting attendees 4/24/25 E Cheng, A Hollard, M Dighe, K Ma, S Swati, S Bornemeier, B Marion, R Betit Fitzgerald, D Edden
Updated	7/9/2025	Updated: CPT codes Changed: AFI range charts Added Image: 4CH apical view with color	Amie Hollard Renee Betit Fitzgerald