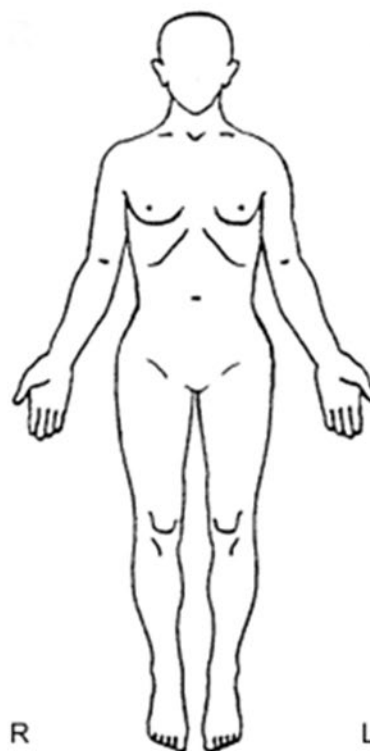
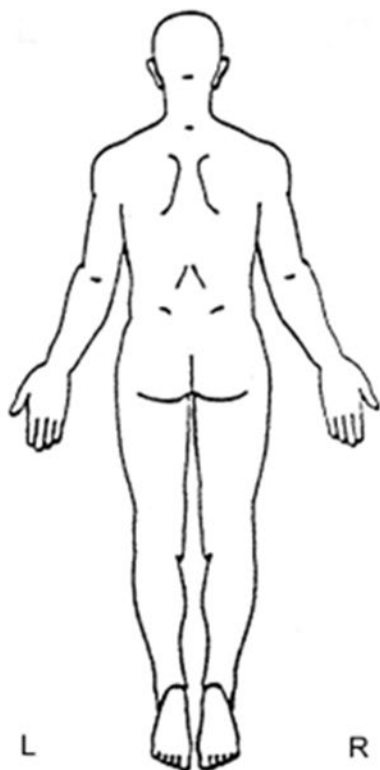


Traumagramm – Body



PHOTOS: YES NO: (Why Not?) _____ Photographer Initials: _____

A – Abrasion, C – Contusion, D – Debris, L – Laceration, P - Petechiae, PI – Patterned Injury, S – Swelling, R – Redness, T – Tenderness		
Site #	Description of Findings	
Examiner Name (Print)	Signature	Date

PLACE PATIENT LABEL HERE

UW Medicine

Harborview Medical Center – University of Washington Medical Center
UW Neighborhood Clinics – Valley Medical Center
University of Washington Physicians Seattle, Washington

DV STRANGULATION REPORT

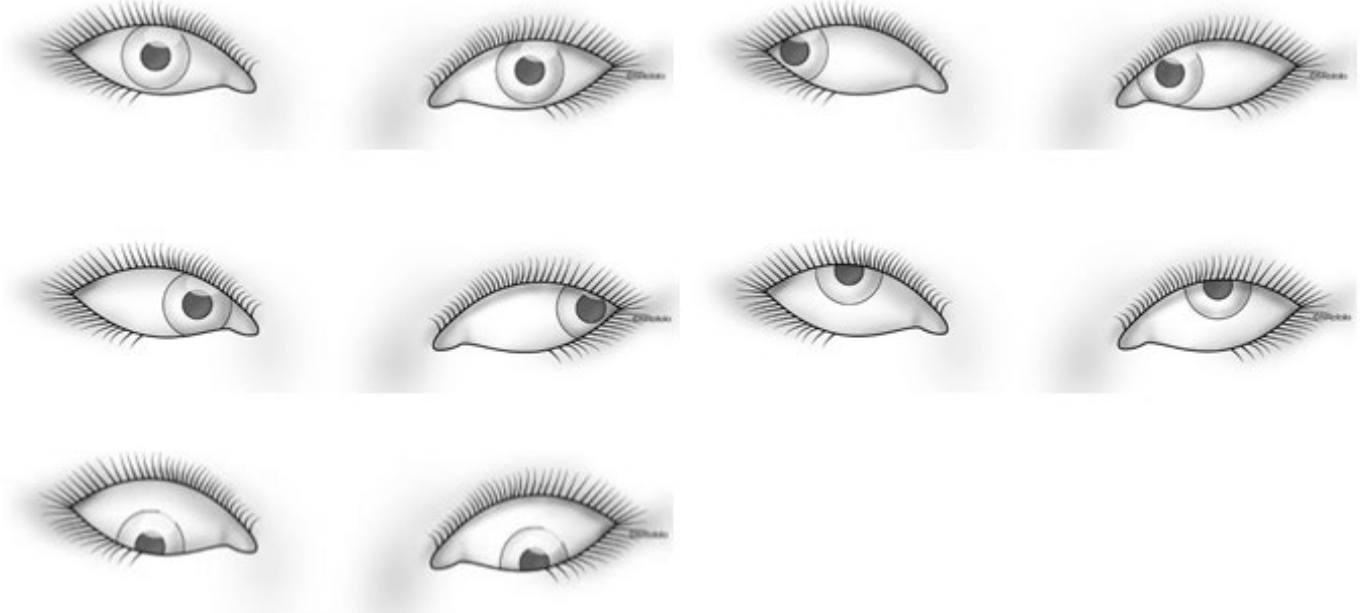
Page 7 of 9



U4236

UH4236 REV DEC 21

Traumagramm – Eyes



A – Abrasion, C – Contusion, L – Laceration, P - Petechiae, PI – Patterned Injury, S – Swelling, R – Redness, T – Tenderness, SH – Subconjunctival Hemorrhage		
Site #	Description of Findings	
Examiner Name (Print)	Signature	Date

PLACE PATIENT LABEL HERE

UW Medicine

Harborview Medical Center – University of Washington Medical Center
UW Neighborhood Clinics – Valley Medical Center
University of Washington Physicians Seattle, Washington

DV STRANGULATION REPORT

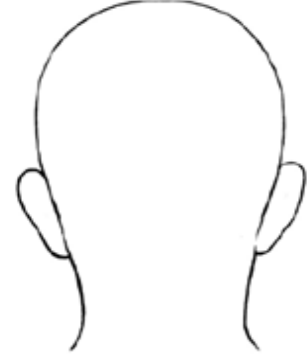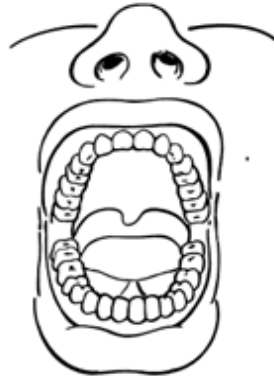
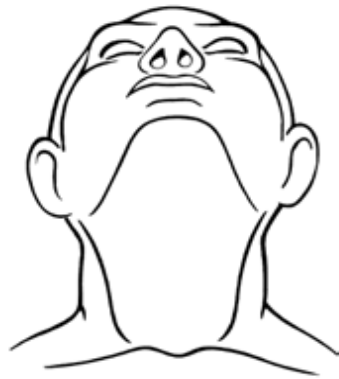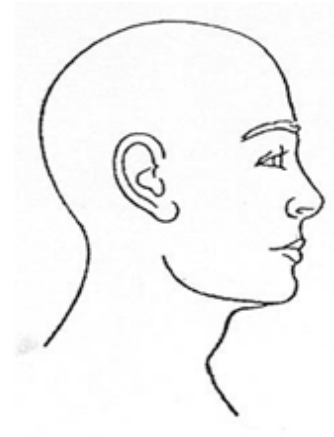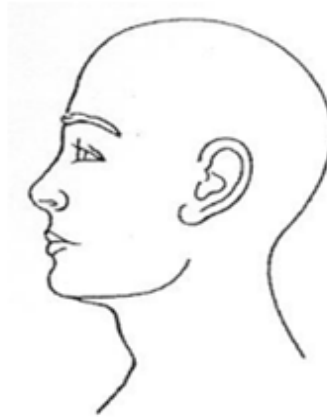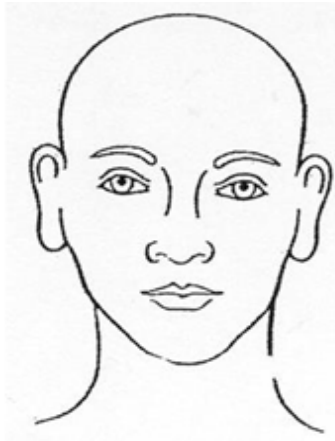Page 8 of 9



U4236

UH4236 REV DEC 21

Traumagramm - Head



A – Abrasion, C – Contusion, D – Debris, L – Laceration, P - Petechiae, PI – Patterned Injury, S – Swelling, R – Redness, T – Tenderness

Site #	Description of Findings
Examiner Name (Print)	Signature
	Date

PLACE PATIENT LABEL HERE

UW Medicine

Harborview Medical Center – University of Washington Medical Center
UW Neighborhood Clinics – Valley Medical Center
University of Washington Physicians Seattle, Washington

DV STRANGULATION REPORT

Page 9 of 9



U4236

UH4236 REV DEC 21